

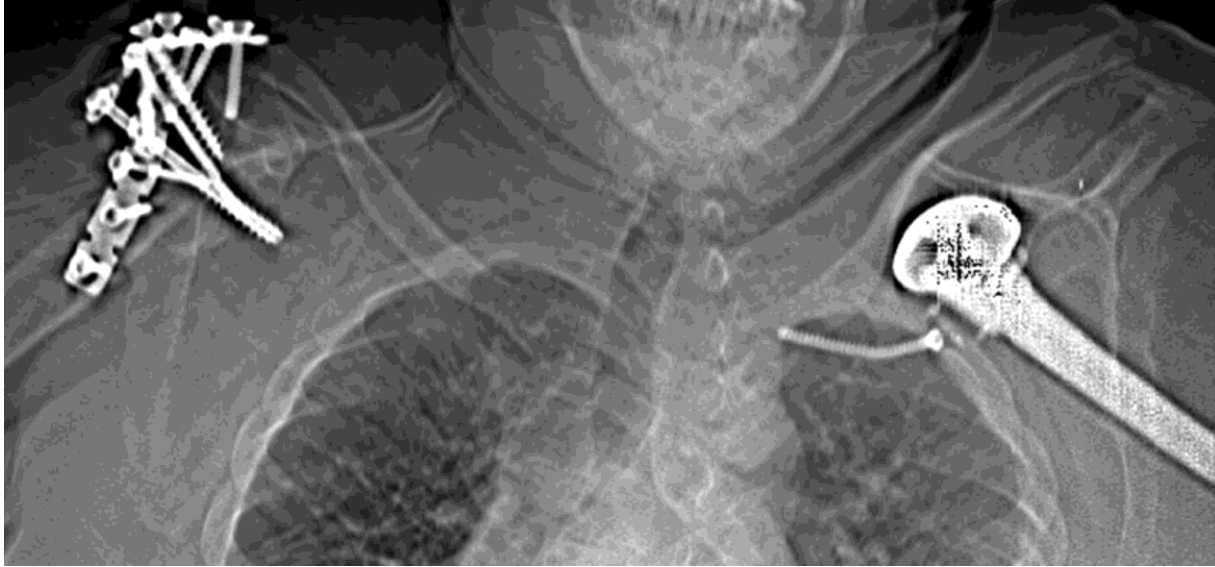Fig. E-1  
Premigration chest radiograph made in 2005.

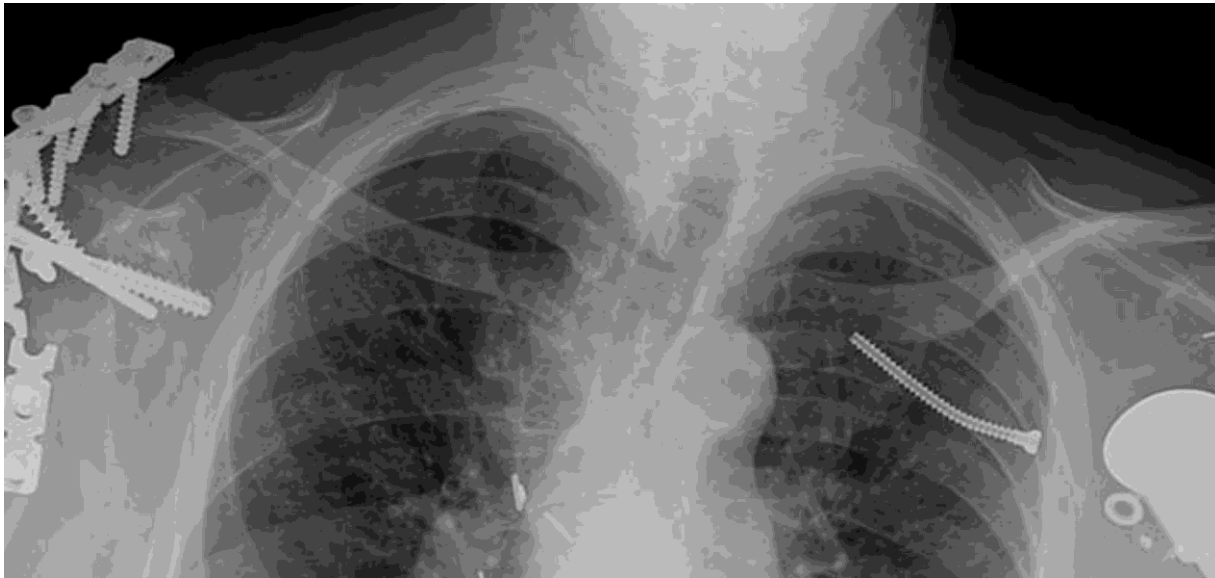


Fig. E-2  
Premigration chest radiograph made in 2007.

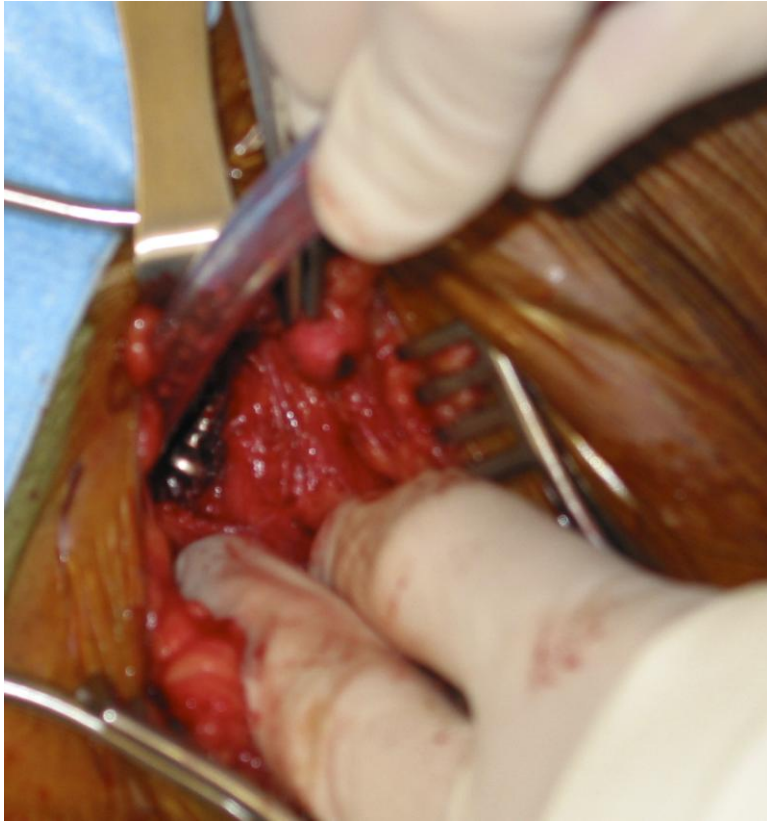

Fig. E-3A

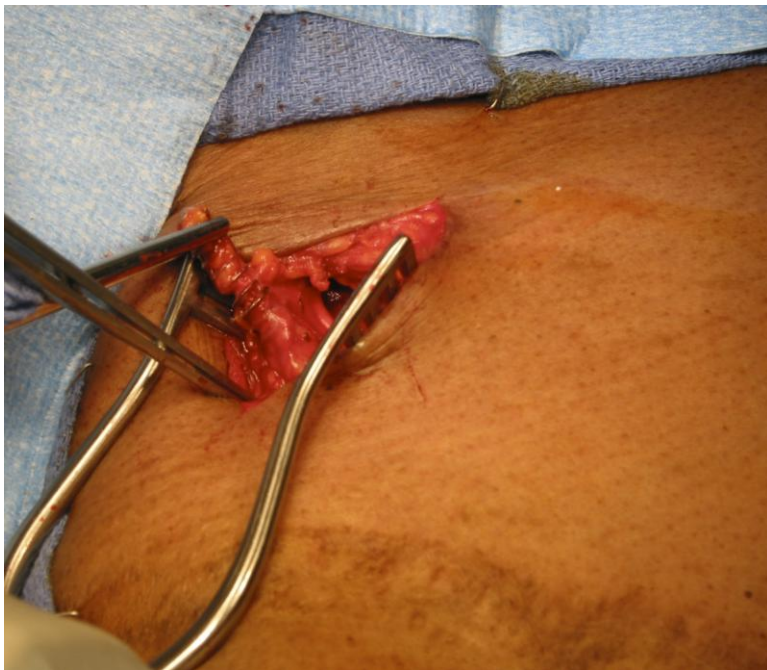


Fig. E-3B

**Figs. E-3A and E-3B** Intraoperative removal of the supraclavicular screw.




Fig. E-4  
Postoperative radiograph after removal of all implants.