

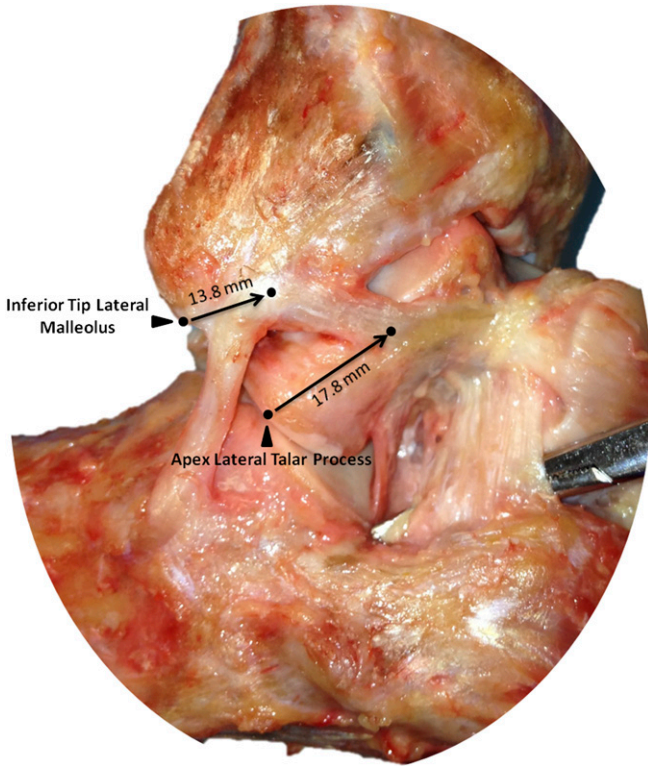Fig. E-1
 Anterolateral view of a right ankle demonstrating the attachment sites of the single-banded anterior talofibular ligament on the fibula and talus.

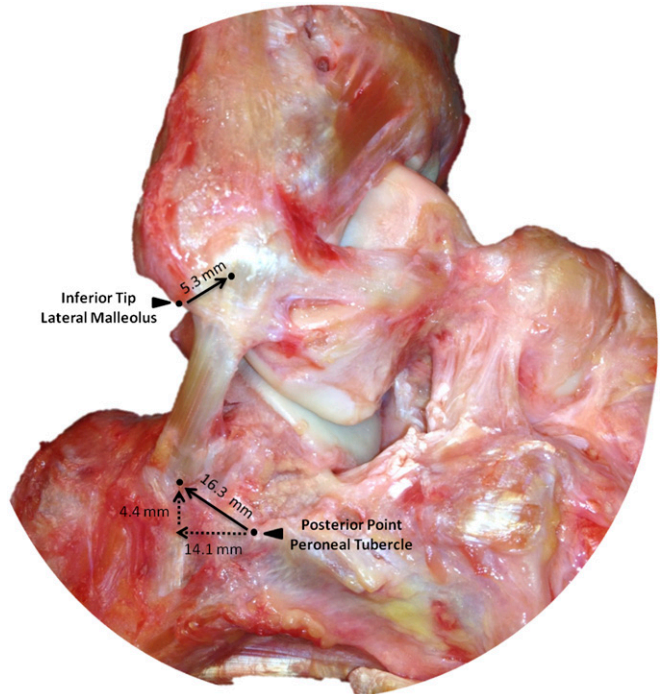


Fig. E-3
 Lateral view of a right ankle demonstrating the attachment sites of the calcaneofibular ligament on the fibula and calcaneus.

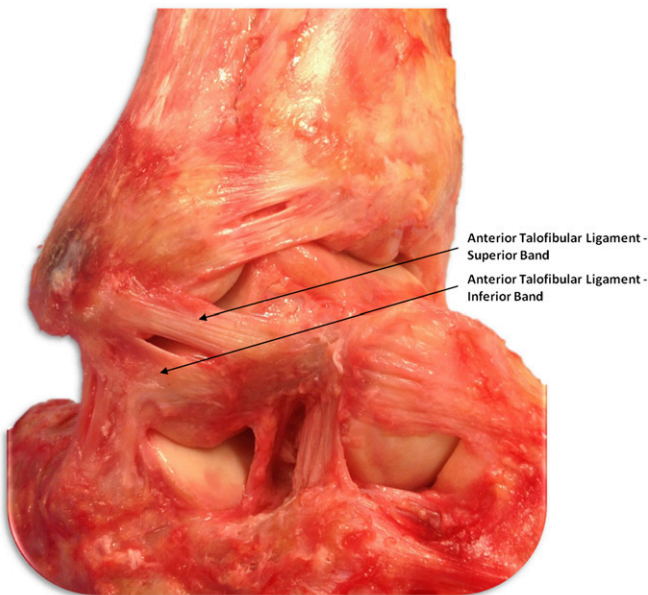


Fig. E-2
 Anterolateral view of a right ankle showing the anatomic attachment sites of the double-banded anterior talofibular ligament on the fibula and talus.

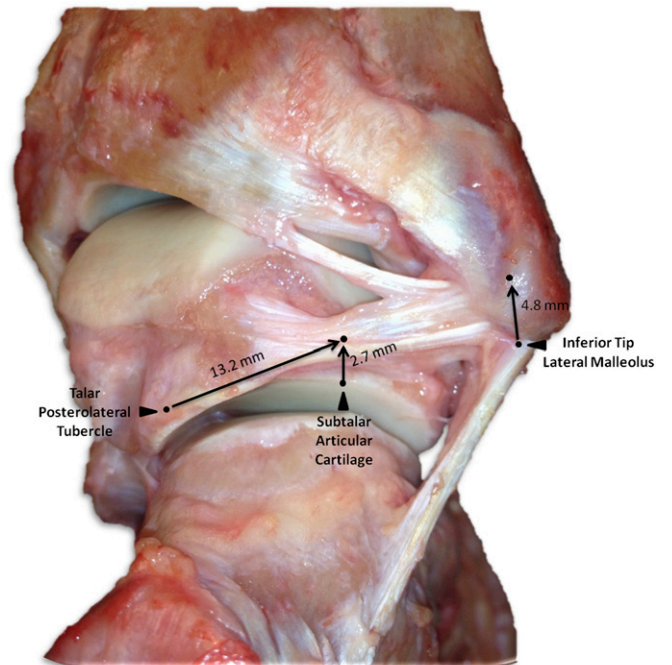


Fig. E-4
 Posterior view of a right ankle showing the attachment sites of the posterior talofibular ligament on the medial side of the lateral malleolus and the posterolateral aspect of the talus.

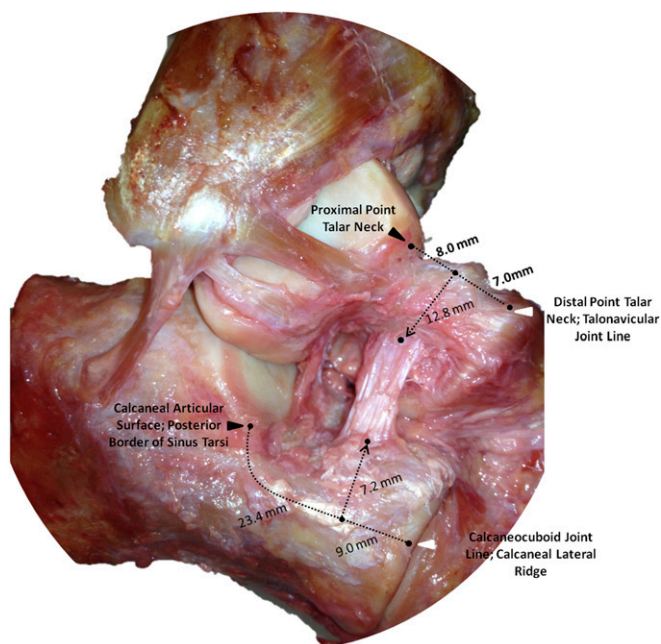


Fig. E-5
Anterolateral view of a right ankle showing the attachment sites of the cervical ligament within the sinus tarsi.