

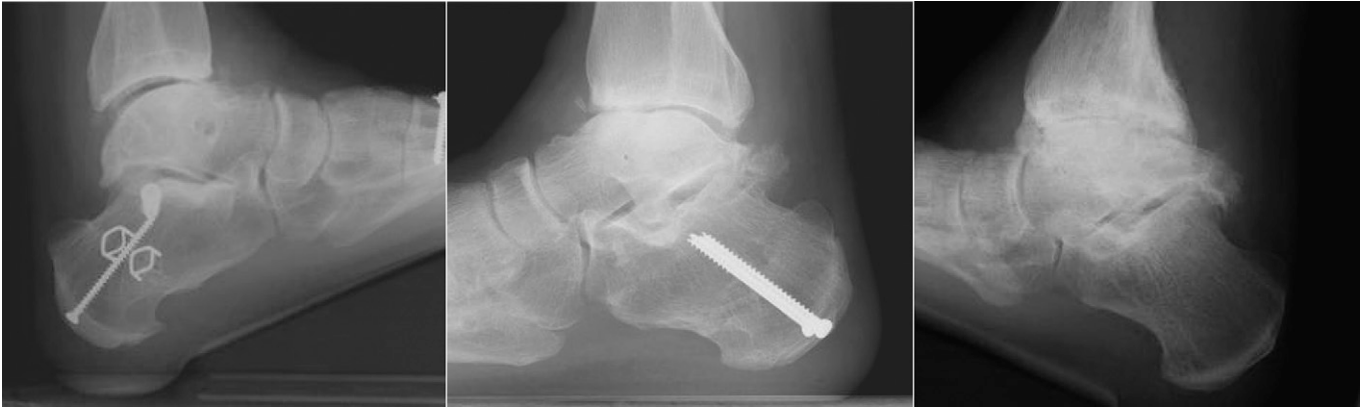

Fig. E-1
Spectrum of radiographic findings at the time of follow-up. **Left** Forty-year-old man who had an AOS score of 29 after 6.7 years of follow-up. **Middle** Sixty-year-old man who elected to proceed with a total ankle arthroplasty after 7.4 years of follow-up. **Right** Sixty-three-year-old man who had an AOS score of 62 after 9.3 years of follow-up and declined additional treatment.

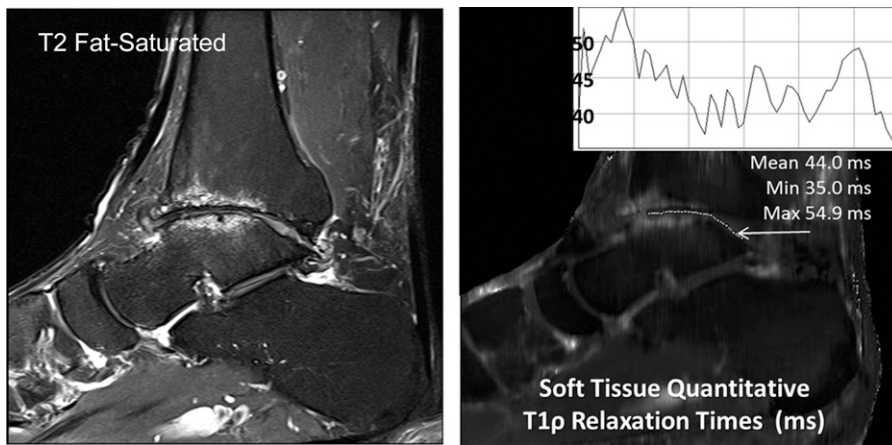


Fig. E-2
T2-weighted fat-saturated images and T1 ρ mapping of the entire joint revealed the presence of cartilage and dense collagen fibers binding water at the time of follow-up MRI.

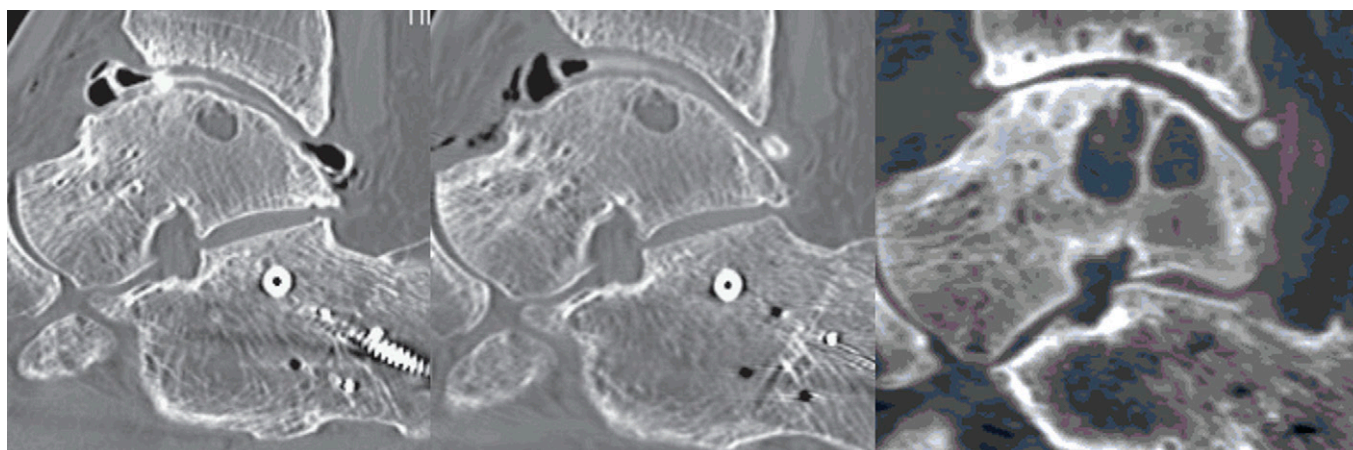


Fig. E-3
Example of progression of ankle arthritis in one patient as seen on CT scans. **Left** Preoperative CT image made in 2006. **Middle** Two-year follow-up CT image made in 2008. **Right** Seven-year follow-up CT image made in 2013.