

Gas Exchange and Respiratory Function

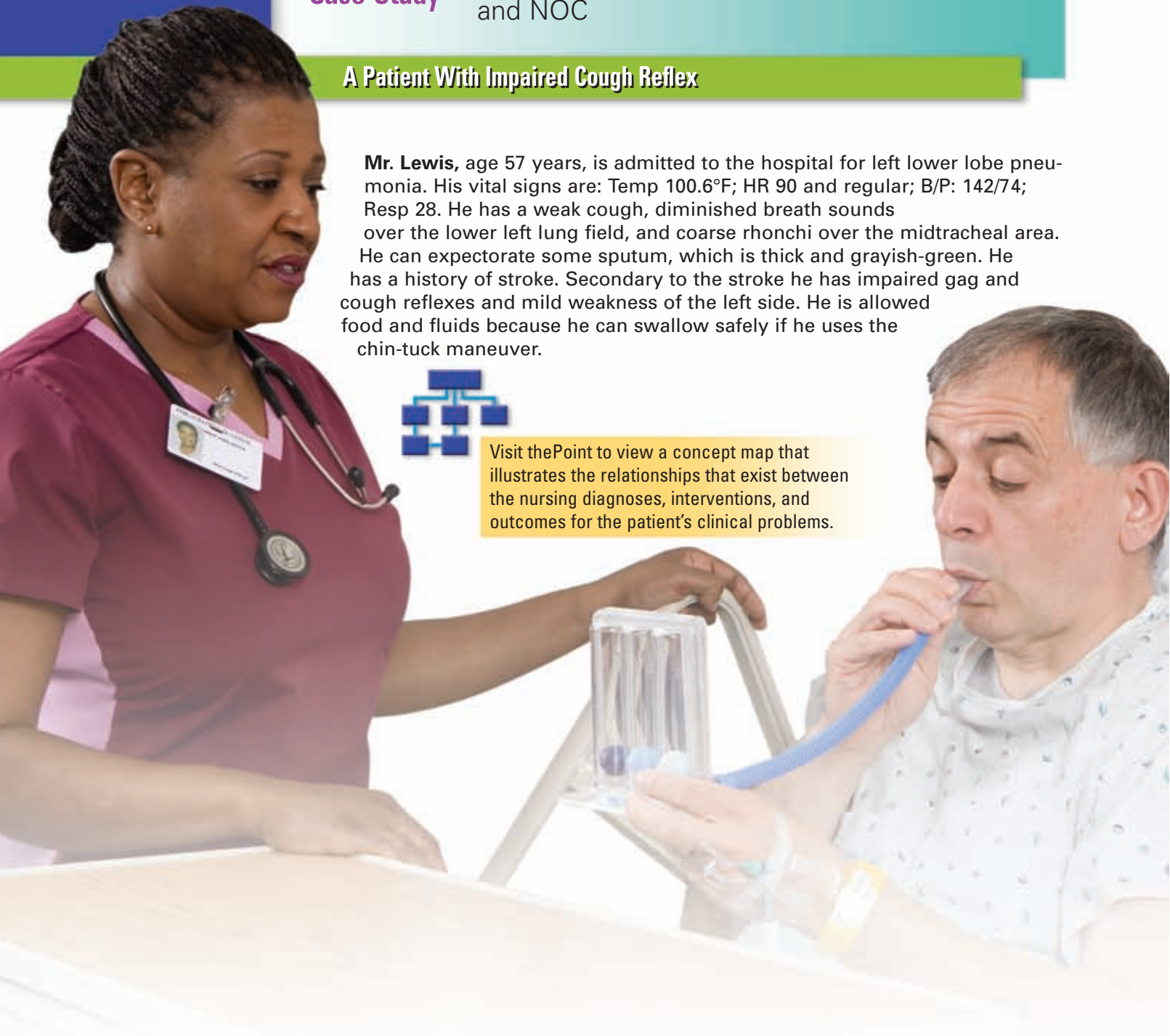
Case Study • Applying Concepts From NANDA, NIC, and NOC

A Patient With Impaired Cough Reflex

Mr. Lewis, age 57 years, is admitted to the hospital for left lower lobe pneumonia. His vital signs are: Temp 100.6°F; HR 90 and regular; B/P: 142/74; Resp 28. He has a weak cough, diminished breath sounds over the lower left lung field, and coarse rhonchi over the midtracheal area. He can expectorate some sputum, which is thick and grayish-green. He has a history of stroke. Secondary to the stroke he has impaired gag and cough reflexes and mild weakness of the left side. He is allowed food and fluids because he can swallow safely if he uses the chin-tuck maneuver.



Visit thePoint to view a concept map that illustrates the relationships that exist between the nursing diagnoses, interventions, and outcomes for the patient's clinical problems.



Nursing Classifications and Languages

NANDA NURSING DIAGNOSES	NIC NURSING INTERVENTIONS	NOC NURSING OUTCOMES
		Return to functional baseline status, stabilization of, or improvement in:
INEFFECTIVE AIRWAY CLEARANCE —Inability to clear secretions or obstructions from the respiratory tract to maintain a clear airway	RESPIRATORY MONITORING —Collection and analysis of patient data to ensure airway patency and adequate gas exchange	RESPIRATORY STATUS: AIRWAY PATENCY —Extent to which the tracheobronchial passages remain open
IMPAIRED GAS EXCHANGE —Excess or deficit in oxygenation and/or carbon dioxide elimination at the alveolar-capillary membrane	AIRWAY MANAGEMENT —Facilitation of patency of air passages	RESPIRATORY STATUS: GAS EXCHANGE —The alveolar exchange of O ₂ and CO ₂ to maintain arterial blood gas concentrations
INEFFECTIVE BREATHING PATTERN —Inspiration and/or expiration that does not provide adequate ventilation	COUGH ENHANCEMENT —Promotion of deep inhalation by the patient with subsequent generation of high intrathoracic pressures and compression of underlying lung parenchyma for the forceful expulsion of air	RESPIRATORY STATUS: VENTILATION —Movement of air in and out of the lungs
RISK FOR ASPIRATION —At risk for entry of gastrointestinal secretions, oropharyngeal secretions, solids, or fluids into tracheobronchial passages	AIRWAY SUCTIONING —Removal of airway secretions by inserting a suction catheter into the patient's oral airway and/or trachea ASPIRATION PRECAUTIONS —Prevention or minimization of risk factors in the patient at risk for aspiration	

Bulechek, G. M., Butcher, H. K., & Dochterman, J. M. (2008). *Nursing interventions classification (NIC)* (5th ed.). St. Louis: Mosby.
 Johnson, M., Bulechek, G., Butcher, H. K., et al. (2006). *NANDA, NOC, and NIC linkages* (2nd ed.). St. Louis: Mosby.
 Moorhead, S., Johnson, M., Mass, M. L., et al. (2008). *Nursing outcomes classification (NOC)* (4th ed.). St. Louis: Mosby.
 NANDA International. (2007). *Nursing diagnoses: Definitions & classification 2007–2008*. Philadelphia: North American Nursing Diagnosis Association.



Assessment of Respiratory Function

LEARNING OBJECTIVES

On completion of this chapter, the learner will be able to:

- 1 Describe the structures and functions of the upper and lower respiratory tracts.
- 2 Describe ventilation, perfusion, diffusion, shunting, and the relationship of pulmonary circulation to these processes.
- 3 Discriminate between normal and abnormal breath sounds.
- 4 Use assessment parameters appropriate for determining the characteristics and severity of the major symptoms of respiratory dysfunction.
- 5 Identify the nursing implications of procedures used for diagnostic evaluation of respiratory function.

GLOSSARY

- apnea:** temporary cessation of breathing
- bronchophony:** abnormal increase in clarity of transmitted voice sounds
- bronchoscopy:** direct examination of larynx, trachea, and bronchi using an endoscope
- cilia:** short hairs that provide a constant whipping motion that serves to propel mucus and foreign substances away from the lung toward the larynx
- compliance:** measure of the force required to expand or inflate the lungs
- crackles:** soft, high-pitched, discontinuous popping sounds during inspiration caused by delayed reopening of the airways
- diffusion:** exchange of gas molecules from areas of high concentration to areas of low concentration
- dyspnea:** labored breathing or shortness of breath
- egophony:** abnormal change in tone of voice that is heard when auscultating lungs
- fremitus:** vibrations of speech felt as tremors of chest wall during palpation
- hemoptysis:** expectoration of blood from the respiratory tract
- hypoxemia:** decrease in arterial oxygen tension in the blood
- hypoxia:** decrease in oxygen supply to the tissues and cells
- obstructive sleep apnea:** temporary absence of breathing during sleep secondary to transient upper airway obstruction
- orthopnea:** inability to breathe easily except in an upright position
- oxygen saturation:** percentage of hemoglobin that is bound to oxygen
- physiologic dead space:** portion of the tracheobronchial tree that does not participate in gas exchange
- pulmonary perfusion:** blood flow through the pulmonary vasculature
- respiration:** gas exchange between atmospheric air and the blood and between the blood and cells of the body
- rhonchi:** low-pitched wheezing or snoring sound associated with partial airway obstruction, heard on chest auscultation
- stridor:** harsh high-pitched sound heard on inspiration, usually without need of stethoscope, secondary to upper airway obstruction
- tachypnea:** abnormally rapid respirations
- tidal volume:** volume of air inspired and expired with each breath during normal breathing
- ventilation:** movement of air in and out of airways
- wheezes:** continuous musical sounds associated with airway narrowing or partial obstruction

Disorders of the respiratory system are common and are encountered by nurses in every setting from the community to the intensive care unit. Expert assessment skills must be developed and used to provide the best care for patients with acute and chronic respiratory problems. In order to differentiate between normal and abnormal assessment findings, an understanding of respiratory function and the significance of abnormal diagnostic test results is essential.

Anatomic and Physiologic Overview

The respiratory system is composed of the upper and lower respiratory tracts. Together, the two tracts are responsible for **ventilation** (movement of air in and out of the airways). The upper respiratory tract, known as the upper airway, warms and filters inspired air so that the lower respiratory tract (the lungs) can accomplish gas exchange. Gas exchange involves delivering oxygen to the tissues through the bloodstream and expelling waste gases, such as carbon dioxide, during expiration. The respiratory system works in concert with the cardiovascular system; the respiratory system is responsible for ventilation and diffusion, and the cardiovascular system is responsible for perfusion (Farquhar & Fantasia, 2005).

Anatomy of the Respiratory System

Upper Respiratory Tract

Upper airway structures consist of the nose, sinuses and nasal passages, pharynx, tonsils and adenoids, larynx, and trachea.

Nose

The nose serves as a passageway for air to pass to and from the lungs. It filters impurities and humidifies and warms the air as it is inhaled. The nose is composed of an external and an internal portion. The external portion protrudes from the face and is supported by the nasal bones and cartilage. The anterior nares (nostrils) are the external openings of the nasal cavities.

The internal portion of the nose is a hollow cavity separated into the right and left nasal cavities by a narrow vertical divider, the septum. Each nasal cavity is divided into three passageways by the projection of the turbinates from the lateral walls. The turbinate bones are also called conchae (the name suggested by their shell-like appearance). Because of their curves, these bones increase the mucous membrane surface of the nasal passages and slightly obstruct the air flowing through them (Fig. 21-1).

Air entering the nostrils is deflected upward to the roof of the nose, and it follows a circuitous route before it reaches the nasopharynx. It comes into contact with a large surface of moist, warm, highly vascular, ciliated mucous membrane (called nasal mucosa) that traps practically all the dust and organisms in the inhaled air. The air is moistened, warmed to body temperature, and brought into contact with sensitive nerves. Some of these nerves detect odors; others provoke sneezing to expel irritating dust. Mucus, secreted continuously by goblet cells, covers the surface of the nasal mucosa and is moved back to the nasopharynx by the action of the **cilia** (fine hairs).

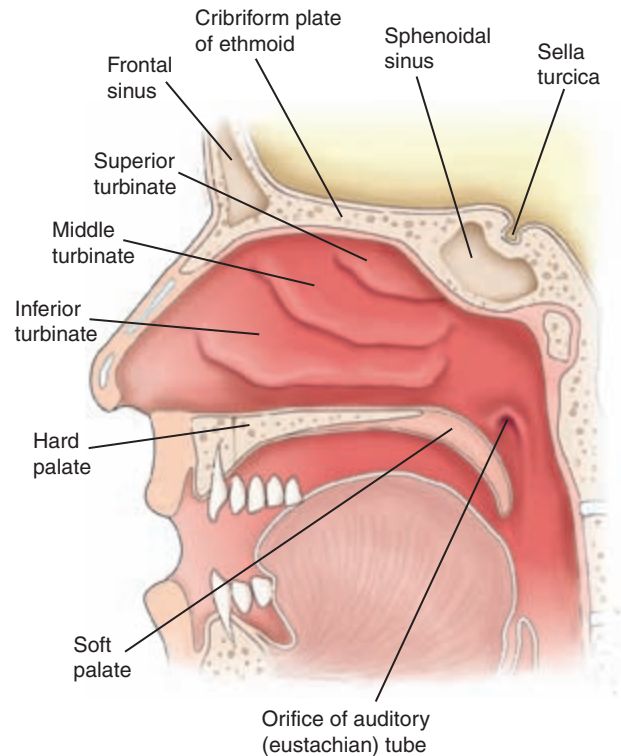


Figure 21-1 Cross-section of nasal cavity.

Paranasal Sinuses

The paranasal sinuses include four pairs of bony cavities that are lined with nasal mucosa and ciliated pseudostratified columnar epithelium. These air spaces are connected by a series of ducts that drain into the nasal cavity. The sinuses are named by their location: frontal, ethmoidal, sphenoidal, and maxillary (Fig. 21-2). A prominent function of the sinuses is to serve as a resonating chamber in speech. The sinuses are a common site of infection.

Pharynx, Tonsils, and Adenoids

The pharynx, or throat, is a tubelike structure that connects the nasal and oral cavities to the larynx. It is divided into three regions: nasal, oral, and laryngeal. The nasopharynx is located posterior to the nose and above the soft palate. The oropharynx houses the faucial, or palatine, tonsils. The laryngopharynx extends from the hyoid bone to the cricoid cartilage. The epiglottis forms the entrance to the larynx.

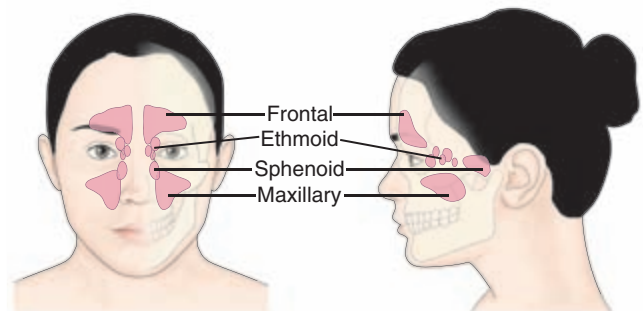


Figure 21-2 The paranasal sinuses.

The adenoids, or pharyngeal tonsils, are located in the roof of the nasopharynx. The tonsils, the adenoids, and other lymphoid tissue encircle the throat. These structures are important links in the chain of lymph nodes guarding the body from invasion by organisms entering the nose and the throat. The pharynx functions as a passageway for the respiratory and digestive tracts.

Larynx

The larynx, or voice organ, is a cartilaginous epithelium-lined structure that connects the pharynx and the trachea. The major function of the larynx is vocalization. It also protects the lower airway from foreign substances and facilitates coughing. It is frequently referred to as the voice box and consists of the following:

- Epiglottis: a valve flap of cartilage that covers the opening to the larynx during swallowing
- Glottis: the opening between the vocal cords in the larynx
- Thyroid cartilage: the largest of the cartilage structures; part of it forms the Adam's apple
- Cricoid cartilage: the only complete cartilaginous ring in the larynx (located below the thyroid cartilage)
- Arytenoid cartilages: used in vocal cord movement with the thyroid cartilage
- Vocal cords: ligaments controlled by muscular movements that produce sounds; located in the lumen of the larynx

Trachea

The trachea, or windpipe, is composed of smooth muscle with C-shaped rings of cartilage at regular intervals. The cartilaginous rings are incomplete on the posterior surface and give firmness to the wall of the trachea, preventing it from collapsing. The trachea serves as the passage between the larynx and the bronchi.

Lower Respiratory Tract

The lower respiratory tract consists of the lungs, which contain the bronchial and alveolar structures needed for gas exchange.

Lungs

The lungs are paired elastic structures enclosed in the thoracic cage, which is an airtight chamber with distensible walls (Fig. 21-3). Ventilation requires movement of the walls of the thoracic cage and of its floor, the diaphragm. The effect of these movements is alternately to increase and decrease the capacity of the chest. When the capacity of the chest is increased, air enters through the trachea (inspiration) because of the lowered pressure within and inflates the lungs. When the chest wall and diaphragm return to their previous positions (expiration), the lungs recoil and force the air out through the bronchi and trachea. Inspiration occurs during the first third of the respiratory cycle, expiration during the later two thirds. The inspiratory phase of respiration normally requires energy; the expiratory phase is normally passive, requiring very little energy.

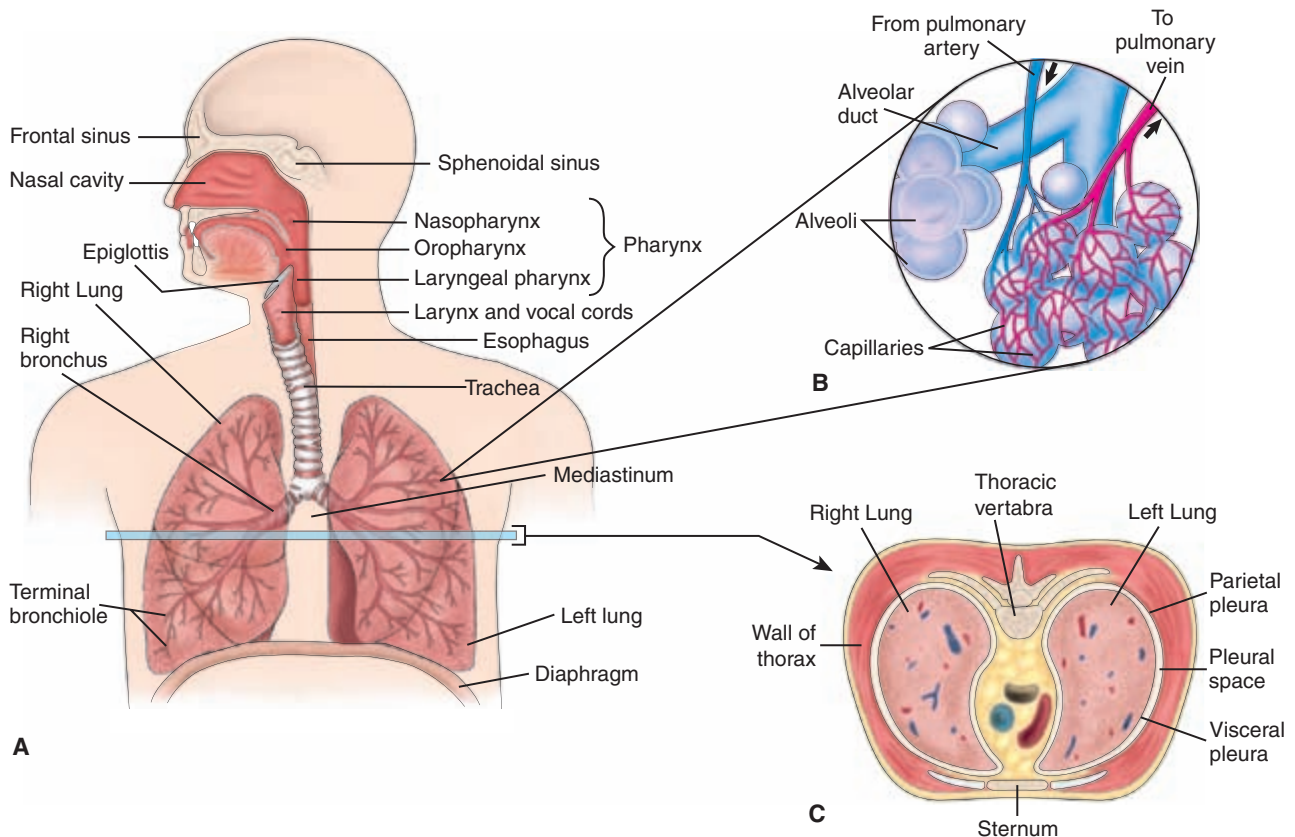


Figure 21-3 The respiratory system; **A**, upper respiratory structures and the structures of the thorax; **B**, alveoli, **C**, and a horizontal cross-section of the lungs.

In respiratory diseases, such as chronic obstructive pulmonary disease (COPD), expiration requires energy.

Pleura. The lungs and wall of the thorax are lined with a serous membrane called the pleura. The visceral pleura covers the lungs; the parietal pleura lines the thorax. The visceral and parietal pleura and the small amount of pleural fluid between these two membranes serve to lubricate the thorax and lungs and permit smooth motion of the lungs within the thoracic cavity with each breath.

Mediastinum. The mediastinum is in the middle of the thorax, between the pleural sacs that contain the two lungs. It extends from the sternum to the vertebral column and contains all the thoracic tissue outside the lungs (heart, thymus, certain large blood vessels [ie, aorta, vena cava], and esophagus).

Lobes. Each lung is divided into lobes. The right lung has upper, middle, and lower lobes, whereas the left lung consists of upper and lower lobes (Fig. 21-4). Each lobe is further subdivided into two to five segments separated by fissures, which are extensions of the pleura.

Bronchi and Bronchioles. There are several divisions of the bronchi within each lobe of the lung. First are the lobar bronchi (three in the right lung and two in the left lung). Lobar bronchi divide into segmental bronchi (10 on the right and 8 on the left), which are the structures identified when choosing the most effective postural drainage position for a given patient. Segmental bronchi then divide into subsegmental bronchi. These bronchi are surrounded by connective tissue that contains arteries, lymphatics, and nerves.

The subsegmental bronchi then branch into bronchioles, which have no cartilage in their walls. Their patency depends entirely on the elastic recoil of the surrounding smooth muscle and on the alveolar pressure. The bronchioles contain

submucosal glands, which produce mucus that covers the inside lining of the airways. The bronchi and bronchioles are also lined with cells that have surfaces covered with cilia. These cilia create a constant whipping motion that propels mucus and foreign substances away from the lungs toward the larynx.

The bronchioles then branch into terminal bronchioles, which do not have mucus glands or cilia. Terminal bronchioles then become respiratory bronchioles, which are considered to be the transitional passageways between the conducting airways and the gas exchange airways. Up to this point, the conducting airways contain about 150 mL of air in the tracheobronchial tree that does not participate in gas exchange; this is known as **physiologic dead space**. The respiratory bronchioles then lead into alveolar ducts and alveolar sacs and then alveoli. Oxygen and carbon dioxide exchange takes place in the alveoli.

Alveoli. The lung is made up of about 300 million alveoli, which are arranged in clusters of 15 to 20. These alveoli are so numerous that if their surfaces were united to form one sheet, it would cover 70 square meters—the size of a tennis court.

There are three types of alveolar cells. Type I alveolar cells are epithelial cells that form the alveolar walls. Type II alveolar cells are metabolically active. These cells secrete surfactant, a phospholipid that lines the inner surface and prevents alveolar collapse. Type III alveolar cell macrophages are large phagocytic cells that ingest foreign matter (eg, mucus, bacteria) and act as an important defense mechanism.

Function of the Respiratory System



The cells of the body derive the energy they need from the oxidation of carbohydrates, fats, and proteins. As with any type of combustion, this process requires oxygen. Certain vital tissues, such as those of the brain and the heart, cannot

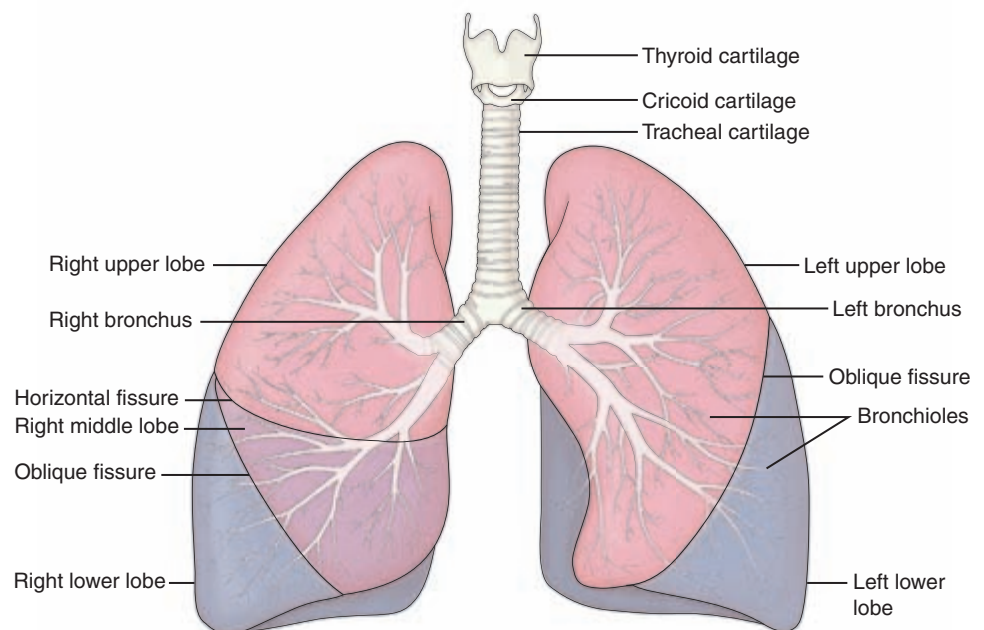


Figure 21-4 Anterior view of the lungs. The lungs consist of five lobes. The right lung has three lobes (upper, middle, lower); the left has two (upper and lower). The lobes are further subdivided by fissures. The bronchial tree, another lung structure, inflates with air to fill the lobes.

survive for long without a continuous supply of oxygen. However, as a result of oxidation in the body tissues, carbon dioxide is produced and must be removed from the cells to prevent the buildup of acid waste products. The respiratory system performs this function by facilitating life-sustaining processes such as oxygen transport, respiration and ventilation, and gas exchange.

Oxygen Transport

Oxygen is supplied to, and carbon dioxide is removed from, cells by way of the circulating blood. Cells are in close contact with capillaries, the thin walls of which permit easy passage or exchange of oxygen and carbon dioxide. Oxygen diffuses from the capillary through the capillary wall to the interstitial fluid. At this point, it diffuses through the membrane of tissue cells, where it is used by mitochondria for cellular respiration. The movement of carbon dioxide occurs by diffusion in the opposite direction—from cell to blood.

Respiration

After these tissue capillary exchanges, blood enters the systemic veins (where it is called venous blood) and travels to the pulmonary circulation. The oxygen concentration in blood within the capillaries of the lungs is lower than in the lungs' air sacs (alveoli). Because of this concentration gradient, oxygen diffuses from the alveoli to the blood. Carbon dioxide, which has a higher concentration in the blood than in the alveoli, diffuses from the blood into the alveoli. Movement of air in and out of the airways (ventilation) continually replenishes the oxygen and removes the carbon dioxide from the airways and lungs. This whole process of gas exchange between the atmospheric air and the blood and between the blood and cells of the body is called **respiration**.

Ventilation

During inspiration, air flows from the environment into the trachea, bronchi, bronchioles, and alveoli. During expiration, alveolar gas travels the same route in reverse.

Physical factors that govern air flow in and out of the lungs are collectively referred to as the mechanics of ventilation and include air pressure variances, resistance to air flow, and lung compliance.

Air Pressure Variances

Air flows from a region of higher pressure to a region of lower pressure. During inspiration, movement of the diaphragm and other muscles of respiration enlarges the thoracic cavity and thereby lowers the pressure inside the thorax to a level below that of atmospheric pressure. As a result, air is drawn through the trachea and bronchi into the alveoli. During expiration, the diaphragm relaxes and the lungs recoil, resulting in a decrease in the size of the thoracic cavity. The alveolar pressure then exceeds atmospheric pressure, and air flows from the lungs into the atmosphere.

Airway Resistance

Resistance is determined chiefly by the radius or size of the airway through which the air is flowing. Any process that changes the bronchial diameter or width affects airway re-

Chart 21-1 • Causes of Increased Airway Resistance

Common phenomena that may alter bronchial diameter, which affects airway resistance, include the following:

- Contraction of bronchial smooth muscle—as in asthma
- Thickening of bronchial mucosa—as in chronic bronchitis
- Obstruction of the airway—by mucus, a tumor, or a foreign body
- Loss of lung elasticity—as in emphysema, which is characterized by connective tissue encircling the airways, thereby keeping them open during both inspiration and expiration

sistance and alters the rate of air flow for a given pressure gradient during respiration (Chart 21-1). With increased resistance, greater-than-normal respiratory effort is required to achieve normal levels of ventilation.

Compliance

Compliance, or distensibility, is the elasticity and expandability of the lungs and thoracic structures. Compliance allows the lung volume to increase when the difference in pressure between the atmosphere and thoracic cavity (pressure gradient) causes air to flow in. Factors that determine lung compliance are the surface tension of the alveoli (normally low with the presence of surfactant) and the connective tissue (ie, collagen and elastin) of the lungs.

Compliance is determined by examining the volume–pressure relationship in the lungs and the thorax. Compliance is normal (1.0 L/cm H₂O) if the lungs and thorax easily stretch and distend when pressure is applied. High or increased compliance occurs if the lungs have lost their elasticity and the thorax is overdistended (eg, in emphysema). Low or decreased compliance occurs if the lungs and thorax are “stiff.” Conditions associated with decreased compliance include morbid obesity, pneumothorax, hemothorax, pleural effusion, pulmonary edema, atelectasis, pulmonary fibrosis, and acute respiratory distress syndrome (ARDS), which are discussed in later chapters in this unit. Measurement of compliance is one method used to assess the progression and improvement in patients with ARDS. Lungs with decreased compliance require greater-than-normal energy expenditure by the patient to achieve normal levels of ventilation. Compliance is usually measured under static conditions.

Lung Volumes and Capacities

Lung function, which reflects the mechanics of ventilation, is viewed in terms of lung volumes and lung capacities. Lung volumes are categorized as tidal volume, inspiratory reserve volume, expiratory reserve volume, and residual volume. Lung capacity is evaluated in terms of vital capacity, inspiratory capacity, functional residual capacity, and total lung capacity. These terms are described in Table 21-1.

Pulmonary Diffusion and Perfusion

Diffusion is the process by which oxygen and carbon dioxide are exchanged at the air–blood interface. The alveolar–capillary membrane is ideal for diffusion because of its

Table 21-1 LUNG VOLUMES AND LUNG CAPACITIES

Term	Symbol	Description	Normal Value*	Significance
Lung Volumes				
Tidal volume	VT or TV	The volume of air inhaled and exhaled with each breath	500 mL or 5–10 mL/kg	The tidal volume may not vary, even with severe disease.
Inspiratory reserve volume	IRV	The maximum volume of air that can be inhaled after a normal inhalation	3000 mL	
Expiratory reserve volume	ERV	The maximum volume of air that can be exhaled forcibly after a normal exhalation	1100 mL	Expiratory reserve volume is decreased with restrictive conditions, such as obesity, ascites, pregnancy.
Residual volume	RV	The volume of air remaining in the lungs after a maximum exhalation	1200 mL	Residual volume may be increased with obstructive disease.
Lung Capacities				
Vital capacity	VC	The maximum volume of air exhaled from the point of maximum inspiration VC = TV + IRV + ERV	4600 mL	A decrease in vital capacity may be found in neuromuscular disease, generalized fatigue, atelectasis, pulmonary edema, COPD, and obesity.
Inspiratory capacity	IC	The maximum volume of air inhaled after normal expiration IC = TV + IRV	3500 mL	A decrease in inspiratory capacity may indicate restrictive disease. May also be decreased in obesity.
Functional residual capacity	FRC	The volume of air remaining in the lungs after a normal expiration FRV = ERV + RV	2300 mL	Functional residual capacity may be increased with COPD and decreased in ARDS and obesity.
Total lung capacity	TLC	The volume of air in the lungs after a maximum inspiration TLC = TV + IRV + ERV + RV	5800 mL	Total lung capacity may be decreased with restrictive disease (atelectasis, pneumonia) and increased in COPD.

* Values for healthy men; women are 20–25% less.

ARDS, acute respiratory distress syndrome; COPD, chronic obstructed pulmonary disease.

thinness and large surface area. In the normal healthy adult, oxygen and carbon dioxide travel across the alveolar–capillary membrane without difficulty as a result of differences in gas concentrations in the alveoli and capillaries.

Pulmonary perfusion is the actual blood flow through the pulmonary circulation. The blood is pumped into the lungs by the right ventricle through the pulmonary artery. The pulmonary artery divides into the right and left branches to supply both lungs. These two branches divide further to supply all parts of each lung. Normally about 2% of the blood pumped by the right ventricle does not perfuse the alveolar capillaries. This shunted blood drains into the left side of the heart without participating in alveolar gas exchange.

The pulmonary circulation is considered a low-pressure system because the systolic blood pressure in the pulmonary artery is 20 to 30 mm Hg and the diastolic pressure is 5 to 15 mm Hg. Because of these low pressures, the pulmonary vasculature normally can vary its capacity to accommodate the blood flow it receives. However, when a person is in an upright position, the pulmonary artery pressure is not great enough to supply blood to the apex of the lung against the force of gravity. Thus, when a person is upright, the lung may be considered to be divided into three sections: an upper part with poor blood supply, a lower part with maximal blood supply, and a section between the two with an intermediate supply of blood. When a person who

is laying down turns to one side, more blood passes to the dependent lung.

Perfusion is also influenced by alveolar pressure. The pulmonary capillaries are sandwiched between adjacent alveoli. If the alveolar pressure is sufficiently high, the capillaries are squeezed. Depending on the pressure, some capillaries completely collapse, whereas others narrow.

Pulmonary artery pressure, gravity, and alveolar pressure determine the patterns of perfusion. In lung disease, these factors vary, and the perfusion of the lung may become very abnormal.

Ventilation and Perfusion Balance and Imbalance

Adequate gas exchange depends on an adequate ventilation–perfusion (\dot{V}/\dot{Q}) ratio. In different areas of the lung, the (\dot{V}/\dot{Q}) ratio varies. Alterations in perfusion may occur with a change in the pulmonary artery pressure, alveolar pressure, or gravity. Airway blockages, local changes in compliance, and gravity may alter ventilation.

(\dot{V}/\dot{Q}) imbalance occurs as a result of inadequate ventilation, inadequate perfusion, or both. There are four possible (\dot{V}/\dot{Q}) states in the lung: normal (\dot{V}/\dot{Q}) ratio, low (\dot{V}/\dot{Q}) ratio (shunt), high (\dot{V}/\dot{Q}) ratio (dead space), and absence of ventilation and perfusion (silent unit) (Chart 21-2). (\dot{V}/\dot{Q}) imbalance causes shunting of blood, resulting in **hypoxia** (low level of cellular oxygen). Shunting appears to be the main cause of hypoxia after thoracic or abdominal surgery

Chart 21-2 • Ventilation-Perfusion Ratios

Normal Ratio (A)

In the healthy lung, a given amount of blood passes an alveolus and is matched with an equal amount of gas (A). The ratio is 1:1 (ventilation matches perfusion).

Low Ventilation-Perfusion Ratio: Shunts (B)

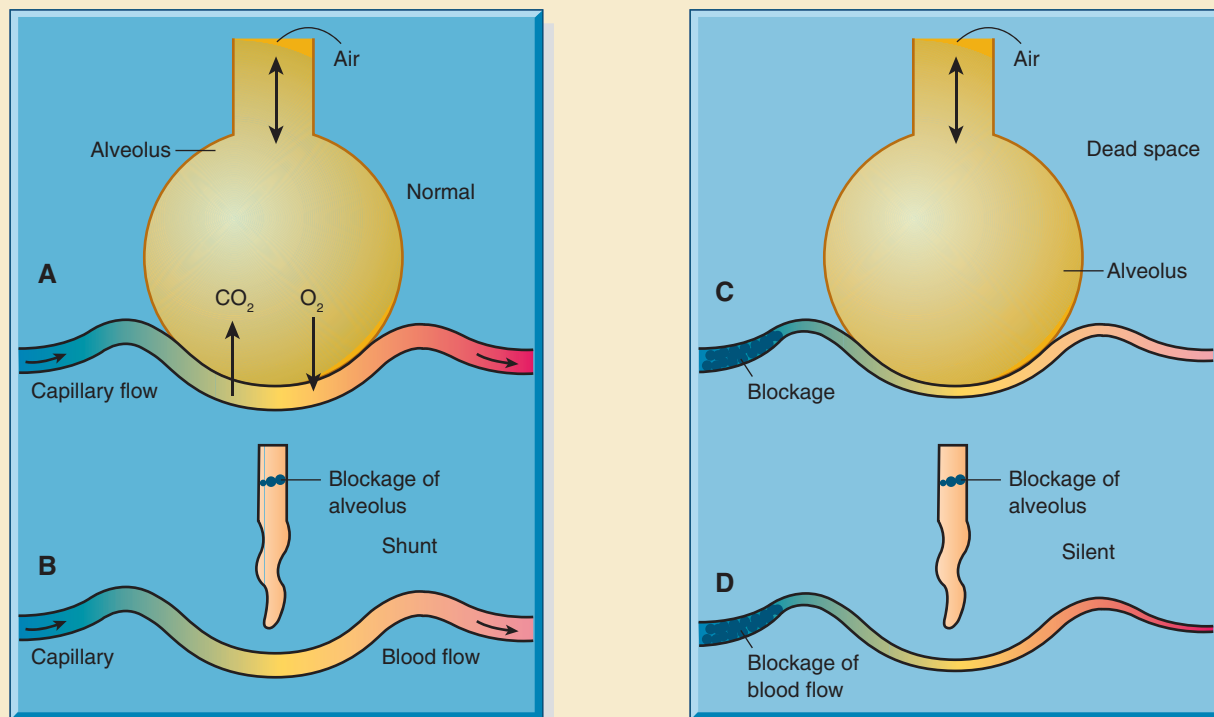
Low ventilation-perfusion states may be called shunt-producing disorders. When perfusion exceeds ventilation, a shunt exists (B). Blood bypasses the alveoli without gas exchange occurring. This is seen with obstruction of the distal airways, such as with pneumonia, atelectasis, tumor, or a mucus plug.

High Ventilation-Perfusion Ratio: Dead Space (C)

When ventilation exceeds perfusion, dead space results (C). The alveoli do not have an adequate blood supply for gas exchange to occur. This is characteristic of a variety of disorders, including pulmonary emboli, pulmonary infarction, and cardiogenic shock.

Silent Unit (D)

In the absence of both ventilation and perfusion or with limited ventilation and perfusion, a condition known as a silent unit occurs (D). This is seen with pneumothorax and severe acute respiratory distress syndrome.



and most types of respiratory failure. Severe hypoxia results when the amount of shunting exceeds 20%. Supplemental oxygen may eliminate hypoxia, depending on the type of (\dot{V}/\dot{Q}) imbalance.

Gas Exchange

Partial Pressure of Gases

The air we breathe is a gaseous mixture consisting mainly of nitrogen (78.6%) and oxygen (20.8%), with traces of carbon dioxide (0.04%), water vapor (0.05%), helium, and argon. The atmospheric pressure at sea level is about 760 mm Hg. Partial pressure is the pressure exerted by each type of gas in a mixture of gases. The partial pressure of a gas is proportional to the concentration of that gas in the mixture. The total pressure exerted by the gaseous mixture, whether in the atmosphere or in the lungs, is equal to the sum of the partial pressures.

Based on these facts, the partial pressures of nitrogen and oxygen can be calculated. The partial pressure of nitrogen in the atmosphere at sea level is 78.6% of 760, or 597 mm Hg; that of oxygen is 20.8% of 760, or 158 mm Hg. Chart 21-3 identifies and defines terms and abbreviations related to partial pressure of gases.

Once the air enters the trachea, it becomes fully saturated with water vapor, which displaces some of the other gases. Water vapor exerts a pressure of 47 mm Hg when it fully saturates a mixture of gases at the body temperature of 37°C (98.6°F). Nitrogen and oxygen are responsible for almost all of the remaining 713 mm Hg pressure. Once this mixture enters the alveoli, it is further diluted by carbon dioxide. In the alveoli, the water vapor continues to exert a pressure of 47 mm Hg. The remaining 713 mm Hg pressure is now exerted as follows: nitrogen, 569 mm Hg (74.9%); oxygen, 104 mm Hg (13.6%); and carbon dioxide, 40 mm Hg (5.3%).

Chart 21-3 • Partial Pressure Abbreviations

P	= pressure
PO ₂	= partial pressure of oxygen
PCO ₂	= partial pressure of carbon dioxide
PAO ₂	= partial pressure of alveolar oxygen
PACO ₂	= partial pressure of alveolar carbon dioxide
PaO ₂	= partial pressure of arterial oxygen
PaCO ₂	= partial pressure of arterial carbon dioxide
PvO ₂	= partial pressure of venous oxygen
PvCO ₂	= partial pressure of venous carbon dioxide
P ₅₀	= partial pressure of oxygen when the hemoglobin is 50% saturated

When a gas is exposed to a liquid, the gas dissolves in the liquid until an equilibrium is reached. The dissolved gas also exerts a partial pressure. At equilibrium, the partial pressure of the gas in the liquid is the same as the partial pressure of the gas in the gaseous mixture. Oxygenation of venous blood in the lung illustrates this point. In the lung, venous blood and alveolar oxygen are separated by a very thin alveolar membrane. Oxygen diffuses across this membrane to dissolve in the blood until the partial pressure of oxygen in the blood is the same as that in the alveoli (104 mm Hg). However, because carbon dioxide is a by-product of oxidation in the cells, venous blood contains carbon dioxide at a higher partial pressure than that in the alveolar gas. In the lung, carbon dioxide diffuses out of venous blood into the alveolar gas. At equilibrium, the partial pressure of carbon dioxide in the blood and in alveolar gas is the same (40 mm Hg). The changes in partial pressure are shown in Figure 21-5.

Effects of Pressure on Oxygen Transport

Oxygen and carbon dioxide are transported simultaneously either dissolved in blood or combined with hemoglobin in red blood cells. Each 100 mL of normal arterial blood car-

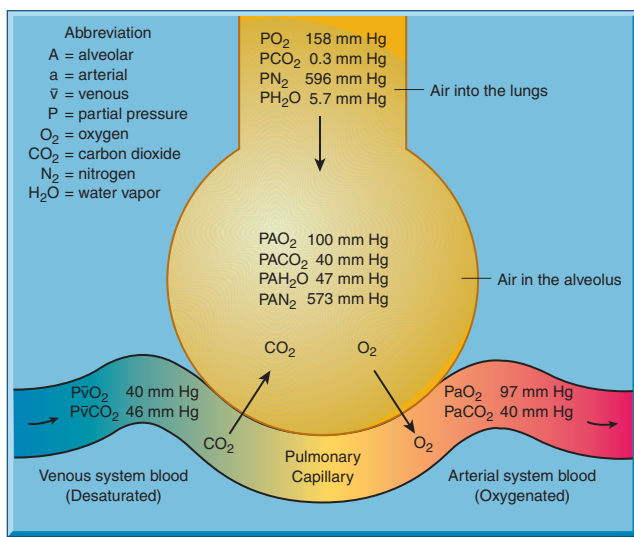
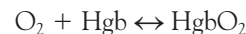


Figure 21-5 Changes occur in the partial pressure of gases during respiration. These values vary as a result of the exchange of oxygen and carbon dioxide and the changes that occur in their partial pressures as venous blood flows through the lungs.

ries 0.3 mL of oxygen physically dissolved in the plasma and 20 mL of oxygen in combination with hemoglobin. Large amounts of oxygen can be transported in the blood because oxygen combines easily with hemoglobin to form oxyhemoglobin:



The volume of oxygen physically dissolved in the plasma is measured by the partial pressure of oxygen in the arteries (PaO₂). The higher the PaO₂, the greater the amount of oxygen dissolved. For example, at a PaO₂ of 10 mm Hg, 0.03 mL of oxygen is dissolved in 100 mL of plasma. At PaO₂ of 20 mm Hg, twice this amount is dissolved in plasma, and at PaO₂ of 100 mm Hg, 10 times this amount is dissolved. Therefore, the amount of dissolved oxygen is directly proportional to the partial pressure, regardless of how high the oxygen pressure becomes.

The amount of oxygen that combines with hemoglobin depends on both the amount of hemoglobin in the blood and on PaO₂, but only up to a PaO₂ of about 150 mm Hg. This is measured as O₂ saturation (SaO₂), the percentage of the O₂ that could be carried if all the hemoglobin held the maximum possible amount of O₂. When the PaO₂ is 150 mm Hg, hemoglobin is 100% saturated and does not combine with any additional oxygen. When hemoglobin is 100% saturated, 1 g of hemoglobin combines with 1.34 mL of oxygen. Therefore, in a person with 14 g/dL of hemoglobin, each 100 mL of blood contains about 19 mL of oxygen associated with hemoglobin. If the PaO₂ is less than 150 mm Hg, the percentage of hemoglobin saturated with oxygen decreases. For example, at a PaO₂ of 100 mm Hg (normal value), saturation is 97%; at a PaO₂ of 40 mm Hg, saturation is 70%.

Oxyhemoglobin Dissociation Curve

The oxyhemoglobin dissociation curve (Chart 21-4) shows the relationship between the partial pressure of oxygen (PaO₂) and the percentage of saturation of oxygen (SaO₂). The percentage of saturation can be affected by carbon dioxide, hydrogen ion concentration, temperature, and 2,3-diphosphoglycerate. An increase in these factors shifts the curve to the right, so that less oxygen is picked up in the lungs, but more oxygen is released to the tissues, if PaO₂ is unchanged. A decrease in these factors causes the curve to shift to the left, making the bond between oxygen and hemoglobin stronger. If the PaO₂ is still unchanged, more oxygen is picked up in the lungs, but less oxygen is given up to the tissues. The unusual shape of the oxyhemoglobin dissociation curve is a distinct advantage to the patient for two reasons:

1. If the PaO₂ decreases from 100 to 80 mm Hg as a result of lung disease or heart disease, the hemoglobin of the arterial blood remains almost maximally saturated (94%), and the tissues do not suffer from hypoxia.
2. When the arterial blood passes into tissue capillaries and is exposed to the tissue tension of oxygen (about 40 mm Hg), hemoglobin gives up large quantities of oxygen for use by the tissues.

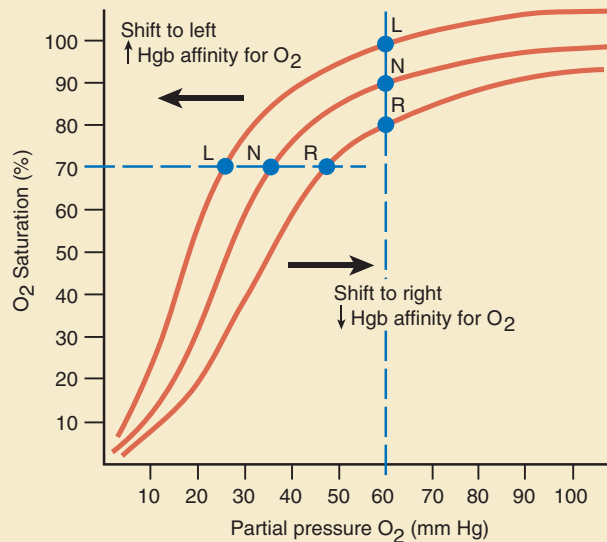
With a normal value for PaO₂ (80 to 100 mm Hg) and SaO₂ (95% to 98%), there is a 15% margin of excess oxygen

Chart 21-4 • Oxyhemoglobin Dissociation Curve

The oxyhemoglobin dissociation curve is marked to show three oxygen levels:

1. Normal levels— PaO_2 above 70 mm Hg
2. Relatively safe levels— PaO_2 45 to 70 mm Hg
3. Dangerous levels— PaO_2 below 40 mm Hg

The normal (middle) curve (N) shows that 75% saturation occurs at a PaO_2 of 40 mm Hg. If the curve shifts to the right (R), the same saturation (75%) occurs at the higher PaO_2 of 57 mm Hg. If the curve shifts to the left (L), 75% saturation occurs at a PaO_2 of 25 mm Hg.



available to the tissues. With a normal hemoglobin level of 15 mg/dL and a PaO_2 level of 40 mm Hg (SaO_2 75%), there is adequate oxygen available for the tissues but no reserve for physiologic stresses that increase tissue oxygen demand. If a serious incident occurs (eg, bronchospasm, aspiration, hypotension, or cardiac dysrhythmias) that reduces the intake of oxygen from the lungs, tissue hypoxia results.

An important consideration in the transport of oxygen is cardiac output, which determines the amount of oxygen delivered to the body and affects lung and tissue perfusion. If the cardiac output is normal (5 L/min), the amount of oxygen delivered to the body per minute is normal. Under normal conditions, only 250 mL of oxygen is used per minute, which is approximately 25% of available oxygen. The rest of the oxygen returns to the right side of the heart, and the PaO_2 of venous blood drops from 80 to 100 mm Hg to about 40 mm Hg. If cardiac output falls, however, the amount of oxygen delivered to the tissues also falls and may be inadequate to meet the body's needs.

Carbon Dioxide Transport

At the same time that oxygen diffuses from the blood into the tissues, carbon dioxide diffuses from tissue cells to blood and is transported to the lungs for excretion. The amount of carbon dioxide in transit is one of the major determinants of the acid–base balance of the body. Normally, only 6% of the venous carbon dioxide is removed in the lungs, and enough remains in the arterial blood to exert a pressure of

40 mm Hg. Most of the carbon dioxide (90%) is carried by red blood cells; the small portion (5%) that remains dissolved in the plasma (partial pressure of carbon dioxide [PCO_2]) is the critical factor that determines carbon dioxide movement in or out of the blood.

Although the many processes involved in respiratory gas transport seem to occur in intermittent stages, the changes are rapid, simultaneous, and continuous.

Neurologic Control of Ventilation

Resting respiration is the result of cyclic excitation of the respiratory muscles by the phrenic nerve. The rhythm of breathing is controlled by respiratory centers in the brain. The inspiratory and expiratory centers in the medulla oblongata and pons control the rate and depth of ventilation to meet the body's metabolic demands.

The apneustic center in the lower pons stimulates the inspiratory medullary center to promote deep, prolonged inspirations. The pneumotaxic center in the upper pons is thought to control the pattern of respirations.

Several groups of receptor sites assist in the brain's control of respiratory function. The central chemoreceptors, located in the medulla, respond to chemical changes in the cerebrospinal fluid, which result from chemical changes in the blood. These receptors respond to an increase or decrease in the pH and convey a message to the lungs to change the depth and then the rate of ventilation to correct the imbalance. The peripheral chemoreceptors are located in the aortic arch and the carotid arteries and respond first to changes in PaO_2 , then to partial pressure of carbon dioxide (PaCO_2) and pH. The Hering-Breuer reflex is activated by stretch receptors in the alveoli. When the lungs are distended, inspiration is inhibited; as a result, the lungs do not become overdistended. In addition, proprioceptors in the muscles and joints respond to body movements, such as exercise, causing an increase in ventilation. Thus, range-of-motion exercises in an immobile patient stimulate breathing. Baroreceptors, also located in the aortic and carotid bodies, respond to an increase or decrease in arterial blood pressure and cause reflex hypoventilation or hyperventilation.

**Gerontologic Considerations**

A gradual decline in respiratory function begins in early to middle adulthood and affects the structure and function of the respiratory system. The vital capacity of the lungs and strength of the respiratory muscles peak between 20 and 25 years of age and decrease thereafter. With aging (40 years and older), changes occur in the alveoli that reduce the surface area available for the exchange of oxygen and carbon dioxide. At approximately 50 years of age, the alveoli begin to lose elasticity. A decrease in vital capacity occurs with loss of chest wall mobility, which restricts the tidal flow of air. The amount of respiratory dead space increases with age. These changes result in a decreased diffusion capacity for oxygen with increasing age, producing lower oxygen levels in the arterial circulation. Elderly people have a decreased ability to rapidly move air in and out of the lungs.

Gerontologic changes in the respiratory system are summarized in Table 21-2. Despite these changes, in the absence of chronic pulmonary disease, elderly people are able

Table 21-2 AGE-RELATED CHANGES IN THE RESPIRATORY SYSTEM

	Structural Changes	Functional Changes	History and Physical Findings
Defense mechanisms (respiratory and nonrespiratory)	<ul style="list-style-type: none"> ↓ Number of cilia and ↓ mucus ↓ Cough and gag reflex Loss of surface area of the capillary membrane Lack of a uniform or consistent ventilation and/or blood flow 	<ul style="list-style-type: none"> ↓ Protection against foreign particles ↓ Protection against aspiration ↓ Antibody response to antigens ↓ Response to hypoxia and hypercapnia (chemoreceptors) 	<ul style="list-style-type: none"> ↓ Cough reflex and mucus ↑ Infection rate History of respiratory infections, COPD, pneumonia. Risk factors: smoking, environmental exposure, TB exposure
Lung	<ul style="list-style-type: none"> ↓ Size of airway ↑ Diameter of alveolar ducts ↑ Collagen of alveolar walls ↑ Thickness of alveolar membranes ↓ Elasticity of alveolar sacs 	<ul style="list-style-type: none"> ↑ Airway resistance ↑ Pulmonary compliance ↓ Expiratory flow rate ↓ Oxygen diffusion capacity ↑ Dead space Premature closure of airways ↑ Air trapping ↓ Expiratory flow rates Ventilation–perfusion mismatch ↓ Exercise capacity ↑ Anteroposterior (AP) diameter 	<ul style="list-style-type: none"> Unchanged total lung capacity (TLC) ↑ Residual volume (RV) ↓ Inspiratory reserve volume (IRV) ↓ Expiratory reserve volume (ERV) ↓ Forced vital capacity (FVC) and vital capacity (VC) ↑ Functional residual capacity (FRC) ↓ PaO₂ ↑ CO₂
Chest wall and muscles	<ul style="list-style-type: none"> Calcification of intercostal cartilages Arthritis of costovertebral joints ↓ Continuity of diaphragm Osteoporotic changes ↓ Muscle mass Muscle atrophy 	<ul style="list-style-type: none"> ↑ Rigidity and stiffness of thoracic cage ↓ Respiratory muscle strength ↑ Work of breathing ↓ Capacity for exercise ↓ Peripheral chemosensitivity ↑ Risk for inspiratory muscle fatigue 	<ul style="list-style-type: none"> Kyphosis, barrel chest Skeletal changes ↑ AP diameter Shortness of breath ↑ Abdominal and diaphragmatic breathing ↓ Maximum expiratory flow rates

to carry out activities of daily living, but they may have decreased tolerance for, and require additional rest after, prolonged or vigorous activity.

Assessment

Health History

The health history focuses on the physical and functional problems and the effects of these problems on the patient, including the ability to carry out activities of daily living. Several common symptoms related to the respiratory system are discussed in detail below. If the patient is experiencing severe dyspnea, the nurse may need to modify or abbreviate the questions asked and the timing of the health history to avoid increasing the patient's breathlessness and anxiety.

In addition to identifying the chief reason why the patient is seeking health care, the nurse tries to determine when the health problem or symptom started, how long it lasted, if it was relieved at any time, and how relief was obtained. The nurse obtains information about precipitating factors, duration, severity, and associated factors or symptoms.

Common Symptoms

The major signs and symptoms of respiratory disease are dyspnea, cough, sputum production, chest pain, wheezing, and hemoptysis. The nurse also assesses the impact of signs and symptoms on the patient's ability to perform activities of daily living and to participate in usual work and family activities.

Dyspnea

Dyspnea (subjective feeling of difficult or labored breathing, breathlessness, shortness of breath) is a symptom common to many pulmonary and cardiac disorders, particularly when there is decreased lung compliance or increased airway resistance. The right ventricle of the heart is affected ultimately by lung disease because it must pump blood through the lungs against greater resistance. Dyspnea may also be associated with neurologic or neuromuscular disorders (eg, myasthenia gravis, Guillain-Barré syndrome, muscular dystrophy, postpolio syndrome) that affect respiratory function. Dyspnea can also occur after physical exercise in people without disease (Davis & Holliday, 2005; Porth & Matfin, 2009). It is also common at the end of life in patients with a variety of disorders.

In general, acute diseases of the lungs produce a more severe grade of dyspnea than do chronic diseases. Sudden dyspnea in a healthy person may indicate pneumothorax (air in the pleural cavity), acute respiratory obstruction, allergic reaction, or myocardial infarction. In immobilized patients, sudden dyspnea may denote pulmonary embolism. Dyspnea and **tachypnea** accompanied by progressive hypoxemia in a person who has recently experienced lung trauma, shock, cardiopulmonary bypass, or multiple blood transfusions may signal acute respiratory distress syndrome (ARDS). **Orthopnea** (inability to breathe easily except in an upright position) may be found in patients with heart disease and occasionally in patients with COPD; dyspnea with an expiratory wheeze occurs with COPD. Noisy breathing may result from a narrowing of the airway or localized obstruction of a major bronchus by a tumor or foreign body. The high-pitched

sound heard (usually on inspiration) when someone is breathing through a partially blocked upper airway is called **stridor**. The presence of both inspiratory and expiratory wheezing usually signifies asthma if the patient does not have heart failure. Because dyspnea can occur with other disorders (eg, cardiac disease, anaphylactic reactions, severe anemia), these disorders also need to be considered when obtaining the patient's health history (Davis & Holliday, 2005).

The circumstance that produces the dyspnea must be determined. Therefore, it is important to ask the patient the following questions:

- How much exertion triggers shortness of breath? Does it occur at rest? With exercise? Running? Climbing stairs?
- Is there an associated cough?
- Is the shortness of breath related to other symptoms?
- Was the onset of shortness of breath sudden or gradual?
- At what time of day or night does the shortness of breath occur?
- Is the shortness of breath worse when laying flat?
- Is the shortness of breath worse while walking? If so, when walking how far? How fast?
- How severe is the shortness of breath? On a scale of 1 to 10, if 1 is breathing without any effort and 10 is breathing that is as difficult as it could possibly be, how hard is it to breathe?

It is especially important to assess the patient's rating of the intensity of breathlessness, the effort required to breathe, and the severity of the breathlessness or dyspnea. Patients use a variety of terms and phrases to describe breathlessness, and the nurse needs to clarify what terms are most familiar to the patient and what these terms mean. Visual analogue or other scales can be used to assess changes in the severity of dyspnea over time (Dorman, Byrne & Edwards, 2007; Porth & Matfin, 2009).

Cough

Cough is a reflex that protects the lungs from the accumulation of secretions or the inhalation of foreign bodies. Its presence or absence can be a diagnostic clue because some disorders cause coughing and others suppress it. The cough reflex may be impaired by weakness or paralysis of the respiratory muscles, prolonged inactivity, the presence of a nasogastric tube, or depressed function of the medullary centers in the brain (eg, anesthesia, brain disorders) (Irwin, Baumann, Bolser, et al., 2006; Porth & Matfin, 2009).

Cough results from irritation of the mucous membranes anywhere in the respiratory tract. The stimulus that produces a cough may arise from an infectious process or from an airborne irritant, such as smoke, smog, dust, or a gas. A persistent and frequent cough can be exhausting and cause pain. Cough may indicate serious pulmonary disease or a variety of other problems as well, including cardiac disease, medication reactions (eg, amiodarone [Cordarone], angiotensin-converting enzyme [ACE] inhibitors), smoking, and gastroesophageal reflux disease (Irwin, et al., 2006).

To help determine the cause of the cough, the nurse describes the cough: dry, hacking, brassy, wheezing, loose, or severe. A dry, irritative cough is characteristic of an upper respiratory tract infection of viral origin, or it may be a side effect of ACE inhibitor therapy. An irritative, high-pitched cough can be caused by laryngotracheitis. A brassy cough is

the result of a tracheal lesion, while a severe or changing cough may indicate bronchogenic carcinoma. Pleuritic chest pain that accompanies coughing may indicate pleural or chest wall (musculoskeletal) involvement.

The nurse inquires about the onset and time of coughing. Coughing at night may indicate the onset of left-sided heart failure or bronchial asthma. A cough in the morning with sputum production may indicate bronchitis. A cough that worsens when the patient is supine suggests postnasal drip (rhinosinusitis). Coughing after food intake may indicate aspiration of material into the tracheobronchial tree. A cough of recent onset is usually from an acute infection.

A persistent cough may affect a patient's quality of life and may produce embarrassment, exhaustion, inability to sleep, and pain. Therefore, the nurse should explore the effect of a chronic cough on the patient and the patient's view about the significance of the cough and its effect on his or her life.

Violent coughing causes bronchial spasm, obstruction, and further irritation of the bronchi and may result in syncope (fainting). A severe, repeated, or uncontrolled cough that is nonproductive is exhausting and potentially harmful.

Sputum Production

A patient who coughs long enough almost invariably produces sputum. Sputum production is the reaction of the lungs to any constantly recurring irritant. It also may be associated with a nasal discharge. The nature of the sputum is often indicative of its cause. A profuse amount of purulent sputum (thick and yellow, green, or rust-colored) or a change in color of the sputum is a common sign of a bacterial infection. Thin, mucoid sputum frequently results from viral bronchitis. A gradual increase of sputum over time may occur with chronic bronchitis or bronchiectasis. Pink-tinged mucoid sputum suggests a lung tumor. Profuse, frothy, pink material, often welling up into the throat, may indicate pulmonary edema. Foul-smelling sputum and bad breath point to the presence of a lung abscess, bronchiectasis, or an infection caused by fusospirochetal or other anaerobic organisms.

Chest Pain

Chest pain or discomfort may be associated with pulmonary or cardiac disease. Chest pain associated with pulmonary conditions may be sharp, stabbing, and intermittent, or it may be dull, aching, and persistent. The pain usually is felt on the side where the pathologic process is located, but it may be referred elsewhere—for example, to the neck, back, or abdomen.

Chest pain may occur with pneumonia, pulmonary embolism with lung infarction, pleurisy, or as a late symptom of bronchogenic carcinoma. In carcinoma, the pain may be dull and persistent because the cancer has invaded the chest wall, mediastinum, or spine.

Lung disease does not always cause thoracic pain because the lungs and the visceral pleura lack sensory nerves and are insensitive to pain stimuli. However, the parietal pleura has a rich supply of sensory nerves that are stimulated by inflammation and stretching of the membrane. Pleuritic pain from irritation of the parietal pleura is sharp and seems to "catch" on inspiration; patients often describe it as being

“like the stabbing of a knife.” Patients are more comfortable when they lay on the affected side because this splints the chest wall, limits expansion and contraction of the lung, and reduces the friction between the injured or diseased pleurae on that side. Pain associated with cough may be reduced manually by splinting the rib cage.

The nurse assesses the quality, intensity, and radiation of pain and identifies and explores precipitating factors and their relationship to the patient’s position. In addition, it is important to assess the relationship of pain to the inspiratory and expiratory phases of respiration.

Wheezing

Wheezing is a high-pitched, musical sound heard mainly on expiration (asthma) or inspiration (bronchitis). It is often the major finding in a patient with bronchoconstriction or airway narrowing. **Rhonchi** are low pitched continuous sounds heard over the lungs in partial airway obstruction. Depending on their location and severity, these sounds may be heard with or without a stethoscope.

Hemoptysis

Hemoptysis (expectoration of blood from the respiratory tract) is a symptom of both pulmonary and cardiac disorders. The onset of hemoptysis is usually sudden, and it may be intermittent or continuous. Signs, which vary from blood-stained sputum to a large, sudden hemorrhage, always merit investigation. The most common causes are:

- Pulmonary infection
- Carcinoma of the lung
- Abnormalities of the heart or blood vessels
- Pulmonary artery or vein abnormalities
- Pulmonary embolus and infarction

Diagnostic evaluation to determine the cause includes chest x-ray, chest angiography, and bronchoscopy. A careful history and physical examination are necessary to identify the underlying disorder, irrespective of whether the bleeding involved a small amount of blood in the sputum or a massive hemorrhage. The amount of blood produced is not always proportional to the seriousness of the cause.

First, it is important to determine the source of the bleeding—the gums, nasopharynx, lungs, or stomach. The nurse may be the only witness to the episode. When documenting the bleeding episode, the nurse considers the following points:

- Bloody sputum from the nose or the nasopharynx is usually preceded by considerable sniffing, with blood possibly appearing in the nose.
- Blood from the lung is usually bright red, frothy, and mixed with sputum. Initial symptoms include a tickling sensation in the throat, a salty taste, a burning or bubbling sensation in the chest, and perhaps chest pain, in which case the patient tends to splint the bleeding side. The term hemoptysis is reserved for the coughing up of blood arising from a pulmonary hemorrhage. This blood has an alkaline pH (greater than 7.0).
- If the hemorrhage is in the stomach, the blood is vomited (hematemesis) rather than coughed up. Blood that has been in contact with gastric juice is sometimes so dark that it is referred to as “coffee ground emesis.” This blood has an acid pH (less than 7.0).

Past Health, Family, and Social History

After exploring the current problem, the nurse obtains a brief history of events and conditions that could affect current health status. Specific questions are asked about childhood illnesses, immunizations, chronic medical conditions, injuries, hospitalizations, surgeries, allergies, and current medications (including over-the-counter medications and herbal remedies). Since many lung disorders are related to or exacerbated by tobacco smoke, smoking history (including exposure to second-hand smoke) is also obtained. Smoking history is usually expressed in pack-years, which is number of packs of cigarettes smoked per day times the number of years the patient smoked. It is important to find out if (and when) the patient quit smoking or is still smoking. The nurse assesses for risk factors and genetic factors that may contribute to the patient’s lung condition (Charts 21-5 and 21-6).

In addition, psychosocial factors that may affect the patient are explored (Chart 21-7). These factors include anxiety, role changes, family relationships, financial problems, employment status, and the strategies the patient uses to cope with them. Many respiratory diseases are chronic and progressively debilitating and disabling. It is important that the patient with a respiratory disorder understand the condition and be familiar with necessary self-care interventions. The nurse evaluates these factors over time and provides education as needed.

Physical Assessment of the Respiratory System

General Appearance

The patient’s general appearance may give clues to respiratory status. In particular, the nurse inspects for clubbing of the fingers and notes skin color.

Clubbing of the Fingers

Clubbing of the fingers is a sign of lung disease that is found in patients with chronic hypoxic conditions, chronic lung infections, or malignancies of the lung (Bickley, 2007). This finding may be manifested initially as sponginess of the nail bed and loss of the nail bed angle (Fig. 21-6).

Cyanosis

Cyanosis, a bluish coloring of the skin, is a very late indicator of hypoxia. The presence or absence of cyanosis is determined by the amount of unoxygenated hemoglobin in the blood. Cyanosis appears when there is at least 5 g/dL of unoxygenated hemoglobin. A patient with a hemoglobin

CHART
21-5



Risk Factors for Respiratory Disease

- Smoking (the single most important contributor to lung disease)
- Exposure to secondhand smoke
- Personal or family history of lung disease
- Genetic makeup
- Exposure to allergens and environmental pollutants
- Exposure to certain recreational and occupational hazards

CHART
21-6GENETICS IN NURSING PRACTICE
Genetic Influences

Various conditions that affect gas exchange and respiratory function are influenced by genetics factors, including:

- Asthma
- Chronic obstructive pulmonary disease
- Cystic fibrosis
- Alpha-1 antitrypsin deficiency

Nursing Assessments**Family History Assessment**

- Assess family history for other family members with histories of respiratory impairment.
- Assess family history for individuals with early-onset chronic pulmonary disease, family history of hepatic disease in infants (clinical symptoms of alpha-1 antitrypsin deficiency).
- Inquire about family history of genetic cystic fibrosis.

Patient Assessment

- Assess for symptoms such as changes in respiratory status associated with asthma (eg, wheezing, hyperresponsiveness, mucosal edema, and mucus production).
- Assess for multisystem effects characteristic of cystic fibrosis (eg, productive cough, wheezing, obstructive airways disease, gastrointestinal problems including pancreatic insufficiency, clubbing of the fingers).

Management Issues Specific to Genetics

- Inquire whether DNA mutation or other genetic testing has been performed on affected family members.

- Refer for further genetics counseling and evaluation so that family members can discuss inheritance, risk to other family members, availability of genetics testing and gene-based interventions.
- Offer appropriate genetics information and resources.
- Assess patient's understanding of genetics information.
- Provide support to families with newly diagnosed genetic-related respiratory disorders.
- Participate in management and coordination of care of patients with genetic conditions, individuals predisposed to develop or pass on a genetic condition.

Genetic Resources

American Lung Association—www.lungusa.org

Cystic Fibrosis Foundation—www.cff.org

Genetic Alliance—a directory of support groups for patients and families with genetic conditions, www.geneticalliance.org

Gene Clinics—a listing of common genetic disorders with clinical summaries, genetics counseling and testing information, www.geneclinics.org

National Organization of Rare Disorders—a directory of support groups and information for patients and families with rare genetic disorders, www.rarediseases.org

OMIM: Online Mendelian Inheritance in Man—a complete listing of inherited genetic conditions, www.ncbi.nlm.nih.gov/entrez/query.fcgi?db=OMIM

level of 15 g/dL does not demonstrate cyanosis until 5 g/dL of that hemoglobin becomes unoxygenated, reducing the effective circulating hemoglobin to two thirds of the normal level.

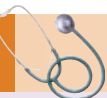A patient with anemia rarely manifests cyanosis, and a patient with polycythemia may appear cyanotic even if adequately oxygenated. Therefore, cyanosis is *not* a reliable sign of hypoxia.

Assessment of cyanosis is affected by room lighting, the patient's skin color, and the distance of the blood vessels from the surface of the skin. In the presence of a pulmonary condition, central cyanosis is assessed by observing the

color of the tongue and lips. This indicates a decrease in oxygen tension in the blood. Peripheral cyanosis results from decreased blood flow to the body's periphery (fingers, toes, or earlobes), as in vasoconstriction from exposure to cold, and does not necessarily indicate a central systemic problem.

Upper Respiratory Structures

For a routine examination of the upper airway, only a simple light source, such as a penlight, is necessary. A more thorough examination requires the use of a nasal speculum.

CHART
21-7**Assessing for Psychosocial Factors Related to Pulmonary Disease and Respiratory Function**

- What strategies does the patient use to cope with the signs and symptoms and challenges associated with pulmonary disease?
- What effect has the pulmonary disease had on the patient's quality of life, goals, role within the family, and occupation?
- What changes has the pulmonary disease had on the patient's family and relationships with family members?
- Does the patient exhibit depression, anxiety, anger, hostility, dependency, withdrawal, isolation, avoidance, noncompliance, acceptance, or denial?
- What support systems does the patient use to cope with the illness?
- Are resources (relatives, friends, or community groups) available? Do the patient and family use them effectively?

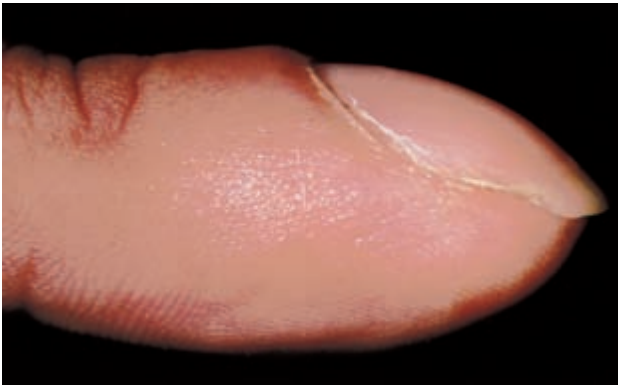


Figure 21-6 Clubbed finger. In clubbing, the distal phalanx of each finger is rounded and bulbous. The nail plate is more convex, and the angle between the plate and the proximal nail fold increases to 180 degrees or more. The proximal nail fold, when palpated, feels spongy or floating. Among the many causes are chronic hypoxia and lung cancer.



Nose and Sinuses

The nurse inspects the external nose for lesions, asymmetry, or inflammation and then asks the patient to tilt the head backward. Gently pushing the tip of the nose upward, the nurse examines the internal structures of the nose, inspecting the mucosa for color, swelling, exudate, or bleeding. The nasal mucosa is normally redder than the oral mucosa. It may appear swollen and hyperemic if the patient has a common cold, but in allergic rhinitis, the mucosa appears pale and swollen.

Next, the nurse inspects the septum for deviation, perforation, or bleeding. Most people have a slight degree of septal deviation, but actual displacement of the cartilage into either the right or left side of the nose may produce nasal obstruction. Such deviation usually causes no symptoms.

While the head is still tilted back, the nurse inspects the inferior and middle turbinates. In chronic rhinitis, nasal polyps may develop between the inferior and middle turbinates; they are distinguished by their gray appearance. Unlike the turbinates, they are gelatinous and freely movable.

Next, the nurse may palpate the frontal and maxillary sinuses for tenderness (Fig. 21-7). Using the thumbs, the

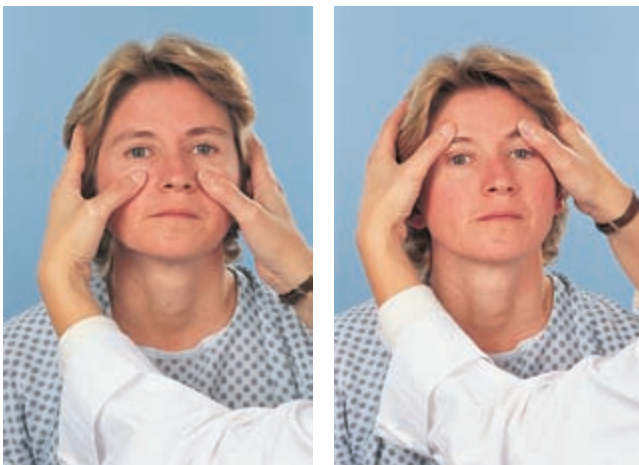

Figure 21-7 Technique for palpating the frontal sinuses at left and the maxillary sinuses at right.

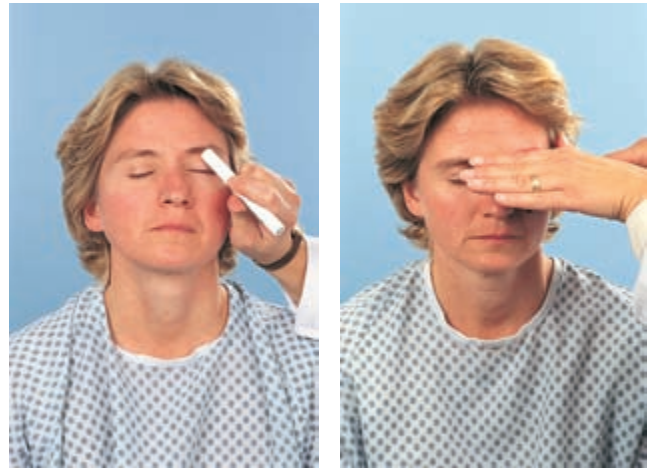

Figure 21-8 At left, the nurse positions the light source for transillumination of the frontal sinus. At right, the nurse shields the patient's brow and shines the light. In normal conditions (a darkened room), the light should shine through the tissues and appear as a reddish glow (above the nurse's hand) over the sinus.

nurse applies gentle pressure in an upward fashion at the supraorbital ridges (frontal sinuses) and in the cheek area adjacent to the nose (maxillary sinuses). Tenderness in either area suggests inflammation. The frontal and maxillary sinuses can be inspected by transillumination (passing a strong light through a bony area, such as the sinuses, to inspect the cavity; Fig. 21-8). If the light fails to penetrate, the cavity likely contains fluid or pus.



Mouth and Pharynx

After the nasal inspection, the nurse assesses the mouth and pharynx, instructing the patient to open the mouth wide and take a deep breath. Usually this flattens the posterior tongue and briefly allows a full view of the anterior and posterior pillars, tonsils, uvula, and posterior pharynx (see Chapter 35, Fig. 35-2). The nurse inspects these structures for color, symmetry, and evidence of exudate, ulceration, or enlargement. If a tongue blade is needed to depress the tongue to visualize the pharynx, it is pressed firmly beyond the midpoint of the tongue to avoid a gagging response.

Trachea

Next, the position and mobility of the trachea are noted by direct palpation. This is performed by placing the thumb and index finger of one hand on either side of the trachea just above the sternal notch. The trachea is highly sensitive, and palpating too firmly may trigger a coughing or gagging response. The trachea is normally in the midline as it enters the thoracic inlet behind the sternum, but it may be deviated by masses in the neck or mediastinum. Pleural or pulmonary disorders, such as a pneumothorax, may also displace the trachea.



Lower Respiratory Structures and Breathing

Assessment of the lower respiratory structures includes inspection, palpation, percussion, and auscultation of the thorax.

Thoracic Inspection

Inspection of the thorax provides information about the musculoskeletal structure, the patient's nutritional status, and the respiratory system. The nurse observes the skin over the thorax for color and turgor and for evidence of loss of subcutaneous tissue. It is important to note asymmetry, if present. In recording or reporting the findings, anatomic landmarks are used as points of reference (Chart 21-8).

Chest Configuration. Normally, the ratio of the anteroposterior diameter to the lateral diameter is 1:2. However, there are four main deformities of the chest associated with respiratory disease that alter this relationship: barrel chest, funnel chest (pectus excavatum), pigeon chest (pectus carinatum), and kyphoscoliosis.

BARREL CHEST. Barrel chest occurs as a result of overinflation of the lungs. There is an increase in the anteroposterior diameter of the thorax. In a patient with emphysema, the ribs are more widely spaced and the intercostal spaces tend to bulge on expiration. The appearance of the patient with advanced emphysema is thus quite characteristic and often allows the observer to detect its presence easily, even from a distance.

FUNNEL CHEST (PECTUS EXCAVATUM). Funnel chest occurs when there is a depression in the lower portion of the sternum. This may compress the heart and great vessels, resulting in murmurs. Funnel chest may occur with rickets or Marfan's syndrome.

PIGEON CHEST (PECTUS CARINATUM). A pigeon chest occurs as a result of displacement of the sternum. There is an increase in the anteroposterior diameter. This may occur with rickets, Marfan's syndrome, or severe kyphoscoliosis.

KYPHOSCOLIOSIS. Kyphoscoliosis is characterized by elevation of the scapula and a corresponding S-shaped spine. This deformity limits lung expansion within the thorax. It may occur with osteoporosis and other skeletal disorders that affect the thorax.

Breathing Patterns and Respiratory Rates. Observing the rate and depth of respiration is a simple but important aspect of assessment. The normal adult who is resting comfortably takes 12 to 18 breaths per minute. Except for occasional sighs, respirations are regular in depth and rhythm. This normal pattern is described as eupnea. The rate and depth of various patterns of respiration are presented in Table 21-3.

Certain patterns of respiration are characteristic of specific disease states. Respiratory rhythms and their deviation from normal are important observations that the nurse reports and documents. Temporary pauses of breathing, or **apnea**, may be noted. When apneas occur repeatedly during sleep, secondary to transient upper airway blockage, the condition is called **obstructive sleep apnea**. In thin people, it is quite normal to note a slight retraction of the intercostal spaces during quiet breathing. Bulging of the intercostal spaces during expiration implies obstruction of expiratory airflow, as in emphysema. Marked retraction on inspiration, particularly if asymmetric, implies blockage of a branch of the respiratory tree. Asymmetric bulging of the intercostal spaces, on one side or the other, is created by an increase in pressure within the hemithorax. This may be a result of air trapped under pressure within the pleural cavity, where it is not normally present

(pneumothorax), or the pressure of fluid within the pleural space (pleural effusion).

Thoracic Palpation

The nurse palpates the thorax for tenderness, masses, lesions, respiratory excursion, and vocal fremitus. If the patient has reported an area of pain or if lesions are apparent, the nurse performs direct palpation with the fingertips (for skin lesions and subcutaneous masses) or with the ball of the hand (for deeper masses or generalized flank or rib discomfort).

Respiratory Excursion. Respiratory excursion is an estimation of thoracic expansion and may disclose significant information about thoracic movement during breathing. The nurse assesses the patient for range and symmetry of excursion. For anterior assessment, the nurse places the thumbs along the costal margin of the chest wall and instructs the patient to inhale deeply. The nurse observes movement of the thumbs during inspiration and expiration. This movement is normally symmetric (Bickley, 2007).

Posterior assessment is performed by placing the thumbs adjacent to the spinal column at the level of the tenth rib (Fig. 21-9). The hands lightly grasp the lateral rib cage. Sliding the thumbs medially about 2.5 cm (1 inch) raises a small skin fold between the thumbs. The patient is instructed to take a full inspiration and to exhale fully. The nurse observes for normal flattening of the skin fold and feels the symmetric movement of the thorax.

Decreased chest excursion may be caused by chronic fibrotic disease. Asymmetric excursion may be due to splinting secondary to pleurisy, fractured ribs, trauma, or unilateral bronchial obstruction (Bickley, 2007).

Tactile Fremitus. Sound generated by the larynx travels distally along the bronchial tree to set the chest wall in resonant motion. This is especially true of consonant sounds. The detection of the resulting vibration on the chest wall by touch is called tactile **fremitus**.

Normal fremitus is widely varied. It is influenced by the thickness of the chest wall, especially if that thickness is muscular. However, the increase in subcutaneous tissue associated with obesity may also affect fremitus. Lower-pitched sounds travel better through the normal lung and produce greater vibration of the chest wall. Therefore, fremitus is more pronounced in men than in women because of the deeper male voice. Normally, fremitus is most pronounced where the large bronchi are closest to the chest wall and least palpable over the distant lung fields. Therefore, it is most palpable in the upper thorax, anteriorly and posteriorly.

The patient is asked to repeat "ninety-nine" or "one, two, three," or "eee, eee, eee" as the nurse's hands move down the patient's thorax. The vibrations are detected with the palmar surfaces of the fingers and hands, or the ulnar aspect of the extended hands, on the thorax. The hand or hands are moved in sequence down the thorax. Corresponding areas of the thorax are compared (Fig. 21-10). Bony areas are not tested.

Air does not conduct sound well, but a solid substance such as tissue does, provided that it has elasticity and is not compressed. Therefore, an increase in solid tissue per unit volume of lung enhances fremitus, and an increase in air per unit volume of lung impedes sound. Patients with emphysema, which results in the rupture of alveoli and trapping of air, exhibit almost no tactile fremitus. A patient with consolidation of a

Chart 21-8 • Locating Thoracic Landmarks

With respect to the thorax, location is defined both horizontally and vertically. With respect to the lungs, location is defined by lobe.

Horizontal Reference Points

Horizontally, thoracic locations are identified according to their proximity to the rib or the intercostal space under the examiner's fingers. On the anterior surface, identification of a specific rib is facilitated by first locating the angle of Louis. This is where the manubrium joins the body of the sternum in the midline. The second rib joins the sternum at this prominent landmark.

Other ribs may be identified by counting down from the second rib. The intercostal spaces are referred to in terms of the rib immediately above the intercostal space; for example, the fifth intercostal space is directly below the fifth rib.

Locating ribs on the posterior surface of the thorax is more difficult. The first step is to identify the spinous process. This is accomplished by finding the seventh cervical vertebra (*vertebra prominens*), which is the most prominent spinous process. When the neck is slightly flexed, the seventh cervical spinous process stands out. Other vertebrae are then identified by counting downward.

Vertical Reference Points

Several imaginary lines are used as vertical referents or landmarks to identify the location of thoracic findings. The *midsternal line* passes through the center of the sternum. The *midclavicular line* is an imaginary line that descends from the middle of the clavicle. The *point of*

maximal impulse of the heart normally lies along this line on the left thorax.

When the arm is abducted from the body at 90 degrees, imaginary vertical lines may be drawn from the anterior axillary fold, from the middle of the axilla, and from the posterior axillary fold. These lines are called, respectively, the *anterior axillary line*, the *midaxillary line*, and the *posterior axillary line*. A line drawn vertically through the superior and inferior poles of the scapula is called the *scapular line*, and a line drawn down the center of the vertebral column is called the *vertebral line*. Using these landmarks, for example, the examiner communicates findings by referring to an area of dullness extending from the vertebral to the scapular line between the seventh and tenth ribs on the right.

Lobes of the Lungs

The lobes of the lung may be mapped on the surface of the chest wall in the following manner. The line between the upper and lower lobes on the left begins at the fourth thoracic spinous process posteriorly, proceeds around to cross the fifth rib in the midaxillary line, and meets the sixth rib at the sternum. This line on the right divides the right middle lobe from the right lower lobe. The line dividing the right upper lobe from the middle lobe is an incomplete one that begins at the fifth rib in the midaxillary line, where it intersects the line between the upper and lower lobes and traverses horizontally to the sternum. Thus, the upper lobes are dominant on the anterior surface of the thorax and the lower lobes are dominant on the posterior surface. There is no presentation of the right middle lobe on the posterior surface of the chest.

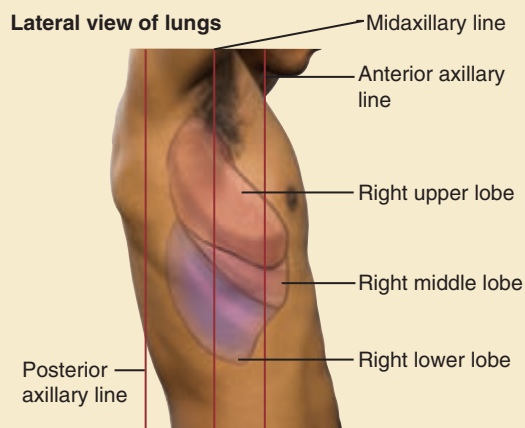
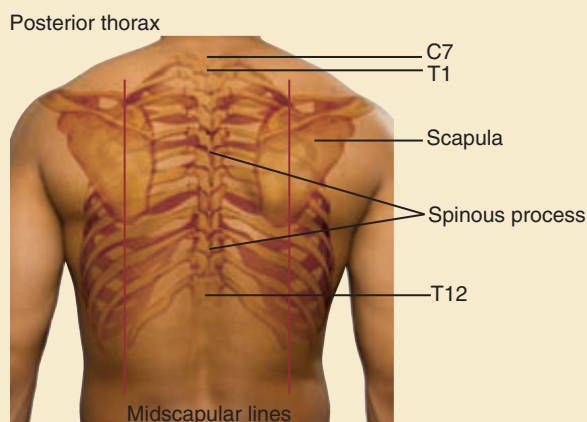
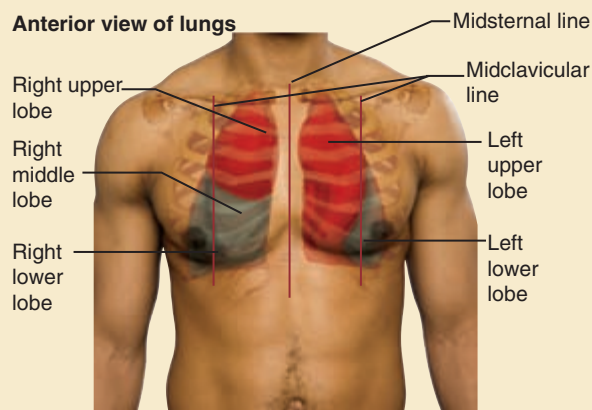
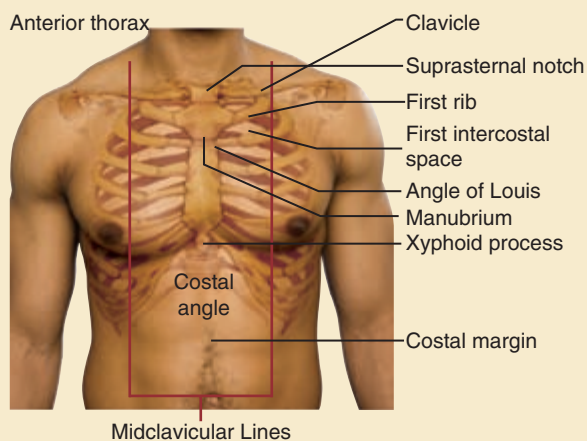
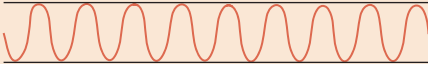

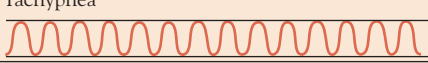



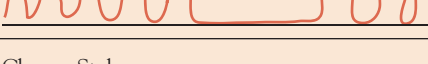

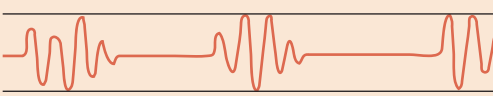


Table 21-3 RATES AND DEPTHS OF RESPIRATION	
Type	Description
Eupnea 	Normal, breathing at 12–18 breaths/min
Bradypnea 	Slower than normal rate (<10 breaths/min), with normal depth and regular rhythm Associated with increased intracranial pressure, brain injury, and drug overdose
Tachypnea 	Rapid, shallow breathing >24 breaths/min Associated with pneumonia, pulmonary edema, metabolic acidosis, septicemia, severe pain, or rib fracture
Hypoventilation 	Shallow, irregular breathing
Hyperpnea 	Increase depth of respirations
Hyperventilation 	Increased rate and depth of breathing that results in decreased PaCO ₂ level Inspiration and expiration are nearly equal in duration Called Kussmaul's respiration if associated with diabetic ketoacidosis or renal origin
Apnea 	Period of cessation of breathing; time duration varies; apnea may occur briefly during other breathing disorders, such as with sleep apnea; life-threatening if sustained
Cheyne-Stokes 	Regular cycle where the rate and depth of breathing increase, then decrease until apnea (usually about 20 seconds) occurs Duration of apnea may vary and progressively lengthen; therefore, it is timed and reported Associated with heart failure and damage to the respiratory center (drug-induced, tumor, trauma)
Biot's respiration 	Periods of normal breathing (3–4 breaths) followed by a varying period of apnea (usually 10–60 seconds) Also called cluster breathing Associated with some nervous system disorders

lobe of the lung from pneumonia has increased tactile fremitus over that lobe. Air in the pleural space does not conduct sound (Bickley, 2007).

Thoracic Percussion

Percussion sets the chest wall and underlying structures in motion, producing audible and tactile vibrations. The nurse uses percussion to determine whether underlying tissues are filled with air, fluid, or solid material. Percussion also is used to estimate the size and location of certain structures within the thorax (eg, diaphragm, heart, liver).

Percussion usually begins with the posterior thorax. Ideally, the patient is in a sitting position with the head flexed forward and the arms crossed on the lap. This position separates the scapulae widely and exposes more lung area for assessment. The nurse percusses across each shoulder top, locating the 5-cm width of resonance overlying the lung apices (Fig. 21-11). Then the nurse proceeds down the posterior thorax, percussing symmetric areas at intervals of 5 to 6 cm (2 to 2.5 inches). The middle finger is positioned parallel to the ribs in the intercostal space; the finger is placed firmly against the chest wall before it is struck with the middle finger of the opposite hand. Bony structures (scapulae or ribs) are not percussed.

Percussion over the anterior chest is performed with the patient in an upright position with shoulders arched backward and arms at the side. The nurse begins in the supraclavicular area and proceeds downward, from one intercostal space to the next. In the female patient, it may be necessary to displace the breasts for an adequate examination. Dullness noted to the left of the sternum between the third and fifth intercostal spaces is a normal finding, because that is the location of the heart. Similarly, there is a normal span of liver dullness in the right thorax, from the fifth intercostal space to the right costal margin at the midclavicular line (Bickley, 2007).

The anterior and lateral thorax is examined with the patient in a supine position. If the patient cannot sit up, percussion of the posterior thorax is performed with the patient positioned on the side.

Dullness over the lung occurs when air-filled lung tissue is replaced by fluid or solid tissue. Table 21-4 reviews percussion sounds and their characteristics.

Diaphragmatic Excursion. The normal resonance of the lung stops at the diaphragm. The position of the diaphragm is different during inspiration and expiration.

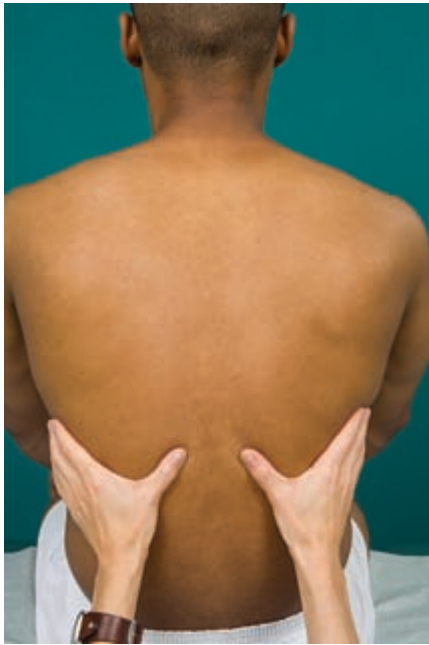

Figure 21-9 Method for assessing posterior respiratory excursion. Place both hands posteriorly at the level of T9 or T10. Slide hands medially to pinch a small amount of skin between your thumbs. Observe for symmetry as the patient exhales fully following a deep inspiration.

To assess the position and motion of the diaphragm, the nurse instructs the patient to take a deep breath and hold it while the maximal descent of the diaphragm is percussed. The point at which the percussion note at the midscapular line changes from resonance to dullness is marked with a pen. The patient is then instructed to exhale fully and hold it while the nurse again percusses downward to the dullness of the di-

aphragm. This point is also marked. The distance between the two markings indicates the range of motion of the diaphragm.

Maximal excursion of the diaphragm may be as much as 8 to 10 cm (3 to 4 inches) in healthy, tall young men, but for most people it is usually 5 to 7 cm (2 to 2.75 inches). Normally, the diaphragm is about 2 cm (0.75 inches) higher on the right because of the position of the heart and the liver above and below the left and right segments of the diaphragm, respectively. Decreased diaphragmatic excursion may occur with pleural effusion and emphysema. An increase in intra-abdominal pressure, as in pregnancy, obesity, or ascites, may account for a diaphragm that is positioned high in the thorax (Bickley, 2007).

Thoracic Auscultation

Assessment concludes with auscultation of the anterior, posterior, and lateral thorax. Auscultation is useful in assessing the flow of air through the bronchial tree and in evaluating the presence of fluid or solid obstruction in the lung. The nurse auscultates for normal breath sounds, adventitious sounds, and voice sounds.

The nurse places the diaphragm of the stethoscope firmly against the chest wall as the patient breathes slowly and deeply through the mouth. Corresponding areas of the chest are auscultated in a systematic fashion from the apices to the bases and along midaxillary lines. The sequence of auscultation and the positioning of the patient are similar to those used for percussion. It often is necessary to listen to two full inspirations and expirations at each anatomic location for valid interpretation of the sound heard. Repeated deep breaths may result in symptoms of hyperventilation (eg, lightheadedness); this is avoided by having the patient rest and breathe normally periodically during the examination.



Breath Sounds. Normal breath sounds are distinguished by their location over a specific area of the lung and

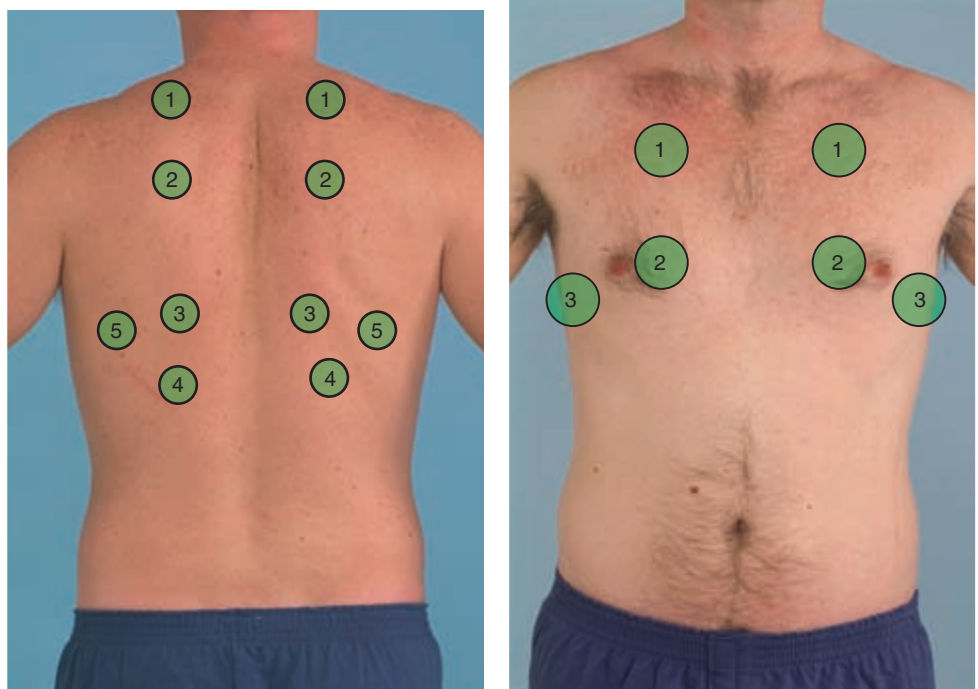


Figure 21-10 Palpation sequence for tactile fremitus: posterior thorax (left) and anterior thorax (right).

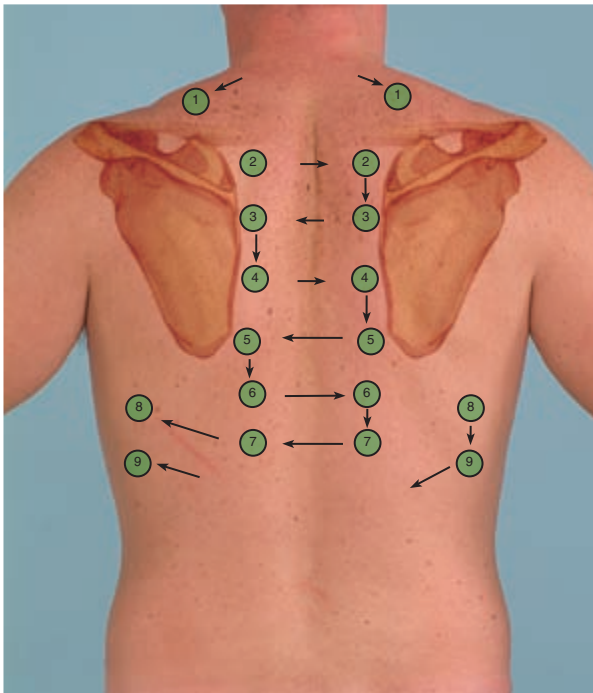


Figure 21-11 Percussion of the posterior thorax. With the patient in a sitting position, symmetric areas of the lungs are percussed at 5-cm intervals. This progression starts at the apex of each lung and concludes with percussion of each lateral chest wall.

are identified as vesicular, bronchovesicular, and bronchial (tubular) breath sounds (Table 21-5).

The location, quality, and intensity of breath sounds are determined during auscultation. When airflow is decreased by bronchial obstruction (atelectasis) or when fluid (pleural effusion) or tissue (obesity) separates the air passages from the stethoscope, breath sounds are diminished or absent. For example, the breath sounds of the patient with emphysema are faint or often completely inaudible. When they are heard, the expiratory phase is prolonged. In the obese or morbidly obese patient, breath sounds may be inaudible. Bronchial and bronchovesicular sounds that are audible anywhere except over the main bronchus in the lungs signify pathology, usually indicating consolidation in the lung (eg, pneumonia, heart failure). This finding requires further evaluation.

Adventitious Sounds. An abnormal condition that affects the bronchial tree and alveoli may produce adventitious (ad-

ditional) sounds. Adventitious sounds are divided into two categories: discrete, noncontinuous sounds (**crackles**) and continuous musical sounds (**wheezes**) (Table 21-6). The duration of the sound is the important distinction to make in identifying the sound as noncontinuous or continuous.

Voice Sounds. The sound heard through the stethoscope as the patient speaks is known as vocal resonance. The vibrations produced in the larynx are transmitted to the chest wall as they pass through the bronchi and alveolar tissue. During the process, the sounds are diminished in intensity and altered so that syllables are not distinguishable. Voice sounds are usually assessed by having the patient repeat “ninety-nine” or “eee” while the nurse listens with the stethoscope in corresponding areas of the chest from the apices to the bases.

Bronchophony describes vocal resonance that is more intense and clearer than normal. **Egophony** describes voice sounds that are distorted. It is best appreciated by having the patient repeat the letter E. The distortion produced by consolidation transforms the sound into a clearly heard A rather than E. Bronchophony and egophony are indicative of consolidation, such as occurs in pneumonia, or pleural effusion. When an abnormality is detected, it should be evident using more than one assessment method. A change in tactile fremitus is more subtle and can be missed, but bronchophony can be noted loudly and clearly.

Whispered pectoriloquy, distinctly hearing words that seem to come from the spot being auscultated, is a very subtle finding, which is heard in the presence of rather dense consolidation of the lungs. This transmission of high-frequency components of whispered sound is not noted in normal physiology. The significance is the same as that of bronchophony (Bickley, 2007).

Interpreting Findings

The physical findings for the most common respiratory diseases are summarized in Table 21-7.







Assessment of Respiratory Function in the Acutely or Critically Ill Patient

Assessment of respiratory status is essential for the well-being of the patient who is acutely or critically ill. Often, such a patient is intubated and receiving mechanical ventilation. This requires that the nurse have expertise in physical assessment, be skilled in monitoring techniques, and be

Table 21-4 CHARACTERISTICS OF PERCUSSION SOUNDS					
Sound	Relative Intensity	Relative Pitch	Relative Duration	Location Example	Examples
Flatness	Soft	High	Short	Thigh	Large pleural effusion
Dullness	Medium	Medium	Medium	Liver	Lobar pneumonia
Resonance	Loud	Low	Long	Normal lung	Simple chronic bronchitis
Hyperresonance	Very loud	Lower	Longer	None normally	Emphysema, pneumothorax
Tympany	Loud	High*	—*	Gastric air bubble or puffed-out cheek	Large pneumothorax

*Distinguished mainly by its musical timbre.

Table 21-5 BREATH SOUNDS

	Duration of Sounds	Intensity of Expiratory Sound	Pitch of Expiratory Sound	Locations Where Heard Normally
Vesicular* 	Inspiratory sounds last longer than expiratory ones	Soft	Relatively low	Entire lung field except over the upper sternum and between the scapulae
Bronchovesicular 	Inspiratory and expiratory sounds are about equal	Intermediate	Intermediate	Often in the 1st and 2nd interspaces anteriorly and between the scapulae (over the main bronchus)
Bronchial 	Expiratory sounds last longer than inspiratory ones	Loud	Relatively high	Over the manubrium, if heard at all
Tracheal 	Inspiratory and expiratory sounds are about equal	Very loud	Relatively high	Over the trachea in the neck

*The thickness of the bars indicates intensity of breath sounds; the steeper their incline, the higher the pitch of the sounds.

knowledgeable about possible ventilator-induced lung injury. The nurse reviews the patient's health history, including the history of disorders affecting lung function, signs and symptoms, and exposure to medications and other agents that can affect respiratory status. The nurse also observes the patient's respiratory status to analyze and interpret a variety of clinical findings and laboratory test results. After checking the ventilator settings to make sure that

they are set as prescribed and that alarms are always in the "on" position, the nurse must assess for patient-ventilator synchrony and for agitation, restlessness, and other signs of respiratory distress (nasal flaring, excessive use of intercostals and accessory muscles, uncoordinated movement of the chest and abdomen, and a report by the patient of shortness of breath). The nurse must note changes in the patient's vital signs and evidence of hemodynamic instability

Table 21-6 ABNORMAL (ADVENTITIOUS) BREATH SOUNDS

Breath Sound	Description	Etiology
Crackles		
Crackles in general	Soft, high-pitched, discontinuous popping sounds that occur during inspiration (while usually heard on inspiration, they may also be heard on expiration); may or may not be cleared by coughing	Secondary to fluid in the airways or alveoli or to delayed opening of collapsed alveoli Associated with heart failure and pulmonary fibrosis
Coarse crackles	Discontinuous popping sounds heard in early inspiration; harsh, moist sound originating in the large bronchi	Associated with obstructive pulmonary disease
Fine crackles	Discontinuous popping sounds heard in late inspiration; sounds like hair rubbing together; originates in the alveoli	Associated with interstitial pneumonia, restrictive pulmonary disease (eg, fibrosis); fine crackles in early inspiration are associated with bronchitis or pneumonia
Wheezes		
Wheezes in general	Usually heard on expiration, but may be heard on inspiration depending on the cause	Associated with bronchial wall oscillation and changes in airway diameter Associated with chronic bronchitis or bronchiectasis Associated with secretions or tumor
Sonorous wheezes (rhonchi)	Deep, low-pitched rumbling sounds heard primarily during expiration; caused by air moving through narrowed tracheobronchial passages	
Sibilant wheezes	Continuous, musical, high-pitched, whistle-like sounds heard during inspiration and expiration caused by air passing through narrowed or partially obstructed airways; may clear with coughing	Associated with bronchospasm, asthma, and buildup of secretions
Friction Rubs		
Pleural friction rub	Harsh, crackling sound, like two pieces of leather being rubbed together (sound imitated by rubbing thumb and finger together near the ear) Heard during inspiration alone or during both inspiration and expiration. May subside when patient holds breath; coughing will not clear sound Best heard over the lower lateral anterior surface of the thorax Sound can be enhanced by applying pressure to the chest wall with the diaphragm of the stethoscope	Secondary to inflammation and loss of lubricating pleural fluid

Table 21-7 ASSESSMENT FINDINGS IN COMMON RESPIRATORY DISORDERS

Disorder	Tactile Fremitus	Percussion	Auscultation
Consolidation (eg, pneumonia)	Increased	Dull	Bronchial breath sounds, crackles, bronchophony, egophony, whispered pectoriloquy
Bronchitis	Normal	Resonant	Normal to decreased breath sounds, wheezes
Emphysema	Decreased	Hyperresonant	Decreased intensity of breath sounds, usually with prolonged expiration
Asthma (severe attack)	Normal to decreased	Resonant to hyperresonant	Wheezes
Pulmonary edema	Normal	Resonant	Crackles at lung bases, possibly wheezes
Pleural effusion	Absent	Dull to flat	Decreased to absent breath sounds, bronchial breath sounds and bronchophony, egophony, and whispered pectoriloquy above the effusion over the area of compressed lung
Pneumothorax	Decreased	Hyperresonant	Absent breath sounds
Atelectasis	Absent	Flat	Decreased to absent breath sounds

and report them to the physician, because they may indicate that the mechanical ventilation is ineffective or that the patient's status has deteriorated. It is necessary to assess the position of the patient to be certain that the head of the bed is elevated to prevent aspiration, especially if the patient is receiving enteral feedings. In addition, the patient's mental status should be assessed and compared to previous status. Lethargy and somnolence may be signs of increasing carbon dioxide levels and should not be considered insignificant, even if the patient is receiving sedation or analgesic agents.

Chest auscultation, percussion, and palpation are essential parts of the evaluation of the critically ill patient with or without mechanical ventilation. Assessment of the anterior and posterior lung fields is part of the nurse's routine evaluation. If the patient is recumbent, it is essential to turn the patient to assess all lung fields. Dependent areas must be assessed for normal breath sounds and adventitious sounds. Failure to examine the dependent areas of the lungs can result in missing the findings associated with disorders such as atelectasis or pleural effusion. Percussion is performed to assess for pleural effusion; if pleural effusion is present, the affected lung fields are dull to percussion and breath sounds are absent. A pleural friction rub may also be present.

Tests of the patient's respiratory status are easily performed at the bedside by measuring the respiratory rate (see earlier discussion), tidal volume, minute ventilation, vital capacity, inspiratory force, and compliance. These tests are particularly important for patients who are at risk for pulmonary complications, including those who have undergone chest or abdominal surgery, have had prolonged anesthesia, have preexisting pulmonary disease, and those who are elderly or obese. These tests are also used routinely for mechanically ventilated patients.

The patient whose chest expansion is limited by external restrictions such as obesity or abdominal distention and who cannot breathe deeply because of postoperative pain or sedation will inhale and exhale a low volume of air (referred to as low tidal volumes). Prolonged hypoventilation at low tidal volumes can produce alveolar collapse (atelectasis). The amount of air remaining in the lungs after a normal expiration (functional residual capacity, FRC) decreases, the ability of the lungs to expand (compliance) is reduced, and the patient must breathe faster to maintain the same degree of tissue oxygenation. These events can be exaggerated in

patients who have preexisting pulmonary diseases, in elderly patients whose airways are less compliant because the small airways may collapse during expiration, or in patients who are obese, who have relatively low tidal volumes even when healthy. More details of the assessment of the patient with lung disease, including arterial blood gas (ABG) analysis, are described in subsequent chapters in this unit and in Chapter 14.

NURSING ALERT

The nurse should not rely only on visual inspection of the rate and depth of a patient's respiratory excursions to determine the adequacy of ventilation. Respiratory excursions may appear normal or exaggerated due to an increased work of breathing, but the patient may actually be moving only enough air to ventilate the dead space. If there is any question regarding adequacy of ventilation, auscultation or pulse oximetry (or both) should be used for additional assessment of respiratory status.

Tidal Volume

The volume of each breath is referred to as the **tidal volume** (see Table 21-1 to review lung capacities and volumes). A spirometer is an instrument that can be used at the bedside to measure volumes. If the patient is breathing through an endotracheal tube or tracheostomy, the spirometer is directly attached to it and the exhaled volume is obtained from the reading on the gauge. In other patients, the spirometer is attached to a face mask or a mouthpiece positioned so that it is airtight, and the exhaled volume is measured.

The tidal volume may vary from breath to breath. To ensure that the measurement is reliable, it is important to measure the volumes of several breaths and to note the range of tidal volumes, together with the average tidal volume.

Minute Ventilation

Respiratory rates and tidal volume alone are unreliable indicators of adequate ventilation, because both can vary widely from breath to breath. However, together the tidal volume and respiratory rate are important because the

CHART
21-9

Risk Factors for Hypoventilation

- Limited neurologic impulses transmitted from the brain to the respiratory muscles, as in spinal cord trauma, cerebrovascular accidents, tumors, myasthenia gravis, Guillain-Barré syndrome, polio, and drug overdose
- Depressed respiratory centers in the medulla, as with anesthesia, sedation, and drug overdose
- Limited thoracic movement (kyphoscoliosis), limited lung movement (pleural effusion, pneumothorax), or reduced functional lung tissue (chronic pulmonary diseases, severe pulmonary edema)

minute ventilation, which is useful in detecting respiratory failure, can be determined from them. Minute ventilation is the volume of air expired per minute. It is equal to the product of the tidal volume in liters multiplied by the respiratory rate or frequency. In practice, the minute ventilation is not calculated but is measured directly using a spirometer. In a patient receiving mechanical ventilation, minute volume is often monitored by the ventilator and can be viewed on the monitoring screen.

Minute ventilation may be decreased by a variety of conditions that result in hypoventilation. When the minute ventilation falls, alveolar ventilation in the lungs also decreases, and the PaCO₂ increases. Risk factors for hypoventilation are listed in Chart 21-9.

Vital Capacity

Vital capacity is measured by having the patient take in a maximal breath and exhale fully through a spirometer. The normal value depends on the patient's age, gender, body build, and weight.

NURSING ALERT

Most patients can generate a vital capacity twice the volume they normally breathe in and out (tidal volume). If the vital capacity is less than 10 mL/kg, the patient will be unable to sustain spontaneous ventilation and will require respiratory assistance.

When the vital capacity is exhaled at a maximal flow rate, the forced vital capacity (FVC) is measured. Most patients can exhale at least 80% of their vital capacity in 1 second (forced expiratory volume in 1 second, or FEV₁) and almost all of it in 3 seconds (FEV₃). A reduction in FEV₁ suggests abnormal pulmonary air flow. If the patient's FEV₁ and forced vital capacity are proportionately reduced, maximal lung expansion is restricted in some way. If the reduction in FEV₁ greatly exceeds the reduction in forced vital capacity (FEV₁/FVC less than 85%), the patient may have some degree of airway obstruction.

Inspiratory Force

Inspiratory force evaluates the effort the patient is making during inspiration. It does not require patient cooperation and therefore is a useful measurement in the unconscious patient. The equipment needed for this measurement in-

cludes a manometer that measures negative pressure and adapters that are connected to an anesthesia mask or a cuffed endotracheal tube. The manometer is attached and the airway is completely occluded for 10 to 20 seconds while the inspiratory efforts of the patient are registered on the manometer. The normal inspiratory pressure is about 100 cm H₂O. If the negative pressure registered after 15 seconds of occluding the airway is less than about 25 cm H₂O, mechanical ventilation is usually required because the patient lacks sufficient muscle strength for deep breathing or effective coughing.

Diagnostic Evaluation

A wide range of diagnostic studies may be performed in patients with respiratory conditions.

Pulmonary Function Tests

Pulmonary function tests (PFTs) are routinely used in patients with chronic respiratory disorders. They are performed to assess respiratory function and to determine the extent of dysfunction. Such tests include measurements of lung volumes, ventilatory function, and the mechanics of breathing, diffusion, and gas exchange.

PFTs are useful in monitoring the course of a patient with an established respiratory disease and assessing the response to therapy. They are useful as screening tests in potentially hazardous industries, such as coal mining and those that involve exposure to asbestos and other noxious fumes, dusts, or gases. Prior to surgery, they are used to screen patients who are scheduled for thoracic and upper abdominal surgical procedures, patients who are obese, and symptomatic patients with a history suggesting high risk. In addition, PFTs may be used for evaluation of respiratory symptoms and disability for insurance or legal purposes (Porth & Matfin, 2009) and to diagnose occupational respiratory disease.

PFTs generally are performed by a technician using a spirometer that has a volume-collecting device attached to a recorder that demonstrates volume and time simultaneously. A number of tests are carried out because no single measurement provides a complete picture of pulmonary function. The most frequently used PFTs are described in Table 21-8. Technology is available that allows for more complex assessment of pulmonary function. Methods include exercise tidal flow-volume loops, negative expiratory pressure, nitric oxide, forced oscillation, and diffusing capacity for helium or carbon monoxide. These assessment methods allow for detailed evaluation of expiratory flow limitations and airway inflammation.

PFT results are interpreted on the basis of the degree of deviation from normal, taking into consideration the patient's height, weight, age, and gender. Because there is a wide range of normal values, PFTs may not detect early localized changes. The patient with respiratory symptoms (dyspnea, wheezing, cough, sputum production) usually undergoes a complete diagnostic evaluation, even if the results of PFTs are "normal." Trends of results provide information about disease progression as well as the patient's response to therapy.

Table 21-8 PULMONARY FUNCTION TESTS

Term Used	Symbol	Description	Remarks
Forced vital capacity	FVC	Vital capacity performed with a maximally forced expiratory effort	Forced vital capacity is often reduced in COPD because of air trapping.
Forced expiratory volume (qualified by subscript indicating the time interval in seconds)	FEV _t (usually FEV ₁)	Volume of air exhaled in the specified time during the performance of forced vital capacity; FEV ₁ is volume exhaled in 1 second	A valuable clue to the severity of the expiratory airway obstruction
Ratio of timed forced expiratory volume to forced vital capacity	FEV _t /FVC%, usually FEV ₁ /FVC%	FEV _t expressed as a percentage of the forced vital capacity	Another way of expressing the presence or absence of airway obstruction
Forced expiratory flow	FEF ₂₀₀₋₁₂₀₀	Mean forced expiratory flow between 200 and 1200 mL of the FVC	An indicator of large airway obstruction
Forced midexpiratory flow	FEF _{25-75%}	Mean forced expiratory flow during the middle half of the FVC	Slowed in small airway obstruction
Forced end expiratory flow	FEF _{75-85%}	Mean forced expiratory flow during the terminal portion of the FVC	Slowed in obstruction of smallest airways
Maximal voluntary ventilation	MVV	Volume of air expired in a specified period (12 seconds) during repetitive maximal effort	An important factor in exercise tolerance

COPD, chronic obstructive pulmonary disease.

Patients with respiratory disorders may be taught how to measure their peak flow rate (which reflects maximal expiratory flow) at home using a spirometer. This allows them to monitor the progress of therapy, to alter medications and other interventions as needed based on caregiver guidelines, and to notify the health care provider if there is inadequate response to their own interventions. Home care teaching instructions are described in Chapter 24, which discusses asthma.

Arterial Blood Gas Studies

Measurements of blood pH and of arterial oxygen and carbon dioxide tensions are obtained when managing patients with respiratory problems and adjusting oxygen therapy as needed. The arterial oxygen tension (partial pressure or PaO₂) indicates the degree of oxygenation of the blood, and the arterial carbon dioxide tension (partial pressure or PaCO₂) indicates the adequacy of alveolar ventilation. ABG studies aid in assessing the ability of the lungs to provide adequate oxygen and remove carbon dioxide and the ability of the kidneys to reabsorb or excrete bicarbonate ions to maintain normal body pH. Serial ABG analysis also is a sensitive indicator of whether the lung has been damaged after chest trauma. ABG levels are obtained through an arterial puncture at the radial, brachial, or femoral artery or through an indwelling arterial catheter. ABG levels are discussed in detail in Chapter 14.

Patients whose ABG levels are monitored repeatedly with blood obtained from arterial punctures should receive an explanation of the purpose of the procedure. Because of the nerves in arterial walls, patients often experience pain with repeated ABG level checks but are often unaware of the purpose of the puncture and the fact that the ABG results could make a major difference in their treatment (Crawford, 2004).

Pulse Oximetry

Pulse oximetry is a noninvasive method of continuously monitoring the **oxygen saturation** of hemoglobin (SaO₂). When oxygen saturation is measured with pulse oximetry, it is referred to as SpO₂ (Clark, Giuliano & Chen, 2006).

Although pulse oximetry does not replace ABG measurement, it is an effective tool to monitor for subtle or sudden changes in oxygen saturation. It is used in all settings where oxygen saturation monitoring is needed, such as the home, clinics, ambulatory surgical settings, and hospitals.

A probe or sensor is attached to the fingertip (Fig. 21-12), forehead, earlobe, or bridge of the nose. The sensor detects changes in oxygen saturation levels by monitoring light signals generated by the oximeter and reflected by blood pulsing through the tissue at the probe. Normal SpO₂ values are 95% to 100%. Values less than 85% indicate that the tissues are not receiving enough oxygen, and further evaluation is needed. SpO₂ values obtained by pulse oximetry are unreliable in cardiac arrest, shock, and other states of low perfusion (eg, sepsis, peripheral vascular disease, hypothermia) and when vasoconstrictor medications have been used. Additional causes of inaccurate pulse oximetry results include anemia, abnormal hemoglobin, high carbon monoxide level, use of dyes (eg, methylene blue), or if the patient has dark skin or is wearing nail polish. Bright light, particularly sunlight, fluorescent and xenon lights, and patient movement (including shivering) also affect accuracy. Furthermore, pulse oximetry values are not reliable detectors of hypoventilation if the patient is receiving supplemental oxygen (Clark, et al., 2006).

Cultures

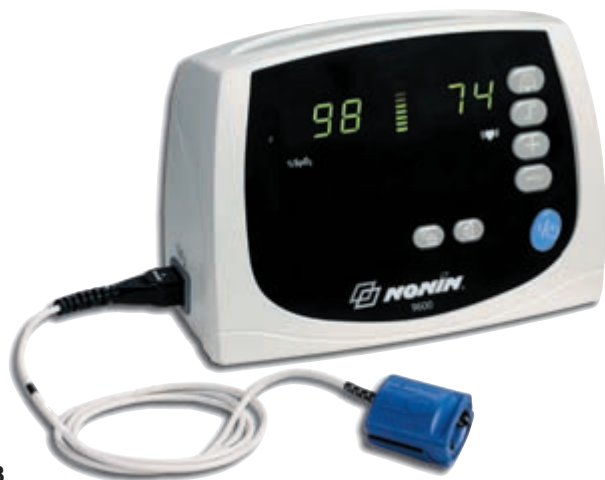Throat cultures (see Chapter 22) may be performed to identify organisms responsible for pharyngitis. Throat culture may also assist in identifying organisms responsible for infection of the lower respiratory tract. Nasal swabs may be performed for the same purpose.

Sputum Studies

Sputum is obtained for analysis to identify pathogenic organisms and to determine whether malignant cells are present. A sputum specimen also may be obtained to assess for hypersensitivity states (in which there is an increase in eosinophils). Periodic sputum examinations may be necessary for patients receiving antibiotics, corticosteroids, and immunosuppressive medications for prolonged periods



A



B

Figure 21-12 Measuring blood oxygenation with pulse oximetry reduces the need for invasive procedures, such as drawing blood for analysis of oxygen levels. **A**, Self-contained digital fingertip pulse oximeter, which incorporates the sensor and the display into one unit. **B**, Table top model with sensor attached. Memory permits tracking heart rate and oxygen saturation over time.

because these agents are associated with opportunistic infections.

Expectoration is the usual method for collecting a sputum specimen. The patient is instructed to clear the nose and throat and rinse the mouth to decrease contamination of the sputum. After taking a few deep breaths, the patient coughs (rather than spits), using the diaphragm, and expectorates into a sterile container.

If the sputum cannot be raised spontaneously, the patient often can be induced to cough deeply by breathing an

irritating aerosol of supersaturated saline, propylene glycol, or some other agent delivered with an ultrasonic nebulizer. Other methods of collecting sputum specimens include endotracheal aspiration, bronchoscopic removal, bronchial brushing, transtracheal aspiration, and gastric aspiration (the last is usually done for tuberculosis organisms; see Chapter 23). Generally, the deepest specimens (those from the base of the lungs) are obtained in the early morning after they have accumulated overnight.

The specimen is delivered to the laboratory within 2 hours by the patient or nurse. Allowing the specimen to stand for several hours in a warm room results in the overgrowth of contaminant organisms and may make it difficult to identify the pathogenic organisms (especially *Mycobacterium tuberculosis*). The home care nurse may assist patients who need help obtaining the sample or who cannot deliver the specimen to the laboratory in a timely fashion.

Imaging Studies

Imaging studies, including x-rays, computed tomography (CT), magnetic resonance imaging (MRI), contrast studies, and radioisotope diagnostic scans may be part of any diagnostic workup, ranging from a determination of the extent of infection in sinusitis to tumor growth in cancer.

Chest X-Ray

Normal pulmonary tissue is radiolucent; therefore, densities produced by fluid, tumors, foreign bodies, and other pathologic conditions can be detected by x-ray examination. A chest x-ray may reveal an extensive pathologic process in the lungs in the absence of symptoms. The routine chest x-ray consists of two views: the posteroanterior projection and the lateral projection. Chest x-rays are usually taken after full inspiration (a deep breath) because the lungs are best visualized when they are well aerated. Also, the diaphragm is at its lowest level and the largest expanse of lung is visible. If taken on expiration, x-ray films may accentuate an otherwise unnoticed pneumothorax or obstruction of a major artery.

Computed Tomography

CT is an imaging method in which the lungs are scanned in successive layers by a narrow-beam x-ray. The images produced provide a cross-sectional view of the chest. Whereas a chest x-ray shows major contrasts between body densities such as bone, soft tissue, and air, CT can distinguish fine tissue density. CT may be used to define pulmonary nodules and small tumors adjacent to pleural surfaces that are not visible on routine chest x-rays and to demonstrate mediastinal abnormalities and hilar adenopathy, which are difficult to visualize with other techniques. Contrast agents are useful when evaluating the mediastinum and its contents.

Magnetic Resonance Imaging

MRI is similar to CT except that magnetic fields and radiofrequency signals are used instead of a narrow-beam x-ray. MRI yields a much more detailed diagnostic image than CT because it visualizes soft tissues. MRI is used to characterize pulmonary nodules, to help stage bronchogenic carcinoma (assessment of chest wall invasion), and to evaluate inflammatory activity in interstitial lung disease, acute

pulmonary embolism, and chronic thrombotic pulmonary hypertension.

Fluoroscopic Studies

Fluoroscopy is used to assist with invasive procedures, such as a chest needle biopsy or transbronchial biopsy, that are performed to identify lesions. It also may be used to study the movement of the chest wall, mediastinum, heart, and diaphragm; to detect diaphragm paralysis; and to locate lung masses.

Pulmonary Angiography

Pulmonary angiography is most commonly used to investigate thromboembolic disease of the lungs, such as pulmonary emboli, and congenital abnormalities of the pulmonary vascular tree. It involves the rapid injection of a radiopaque agent into the vasculature of the lungs for radiographic study of the pulmonary vessels. It can be performed by injecting the radiopaque agent into a vein in one or both arms (simultaneously) or into the femoral vein, with a needle or catheter. The agent also can be injected into a catheter that has been inserted in the main pulmonary artery or its branches or into the great veins proximal to the pulmonary artery.

Radioisotope Diagnostic Procedures (Lung Scans)

Several types of lung scans—(\dot{V}/\dot{Q}) scan, gallium scan, and positron emission tomography (PET)—are used to assess normal lung functioning, pulmonary vascular supply, and gas exchange.

A (\dot{V}/\dot{Q}) lung scan is performed by injecting a radioactive agent into a peripheral vein and then obtaining a scan of the chest to detect radiation. The isotope particles pass through the right side of the heart and are distributed into the lungs in proportion to the regional blood flow, making it possible to trace and measure blood perfusion through the lung. This procedure is used clinically to measure the integrity of the pulmonary vessels relative to blood flow and to evaluate blood flow abnormalities, as seen in pulmonary emboli. The imaging time is 20 to 40 minutes, during which the patient lies under the camera with a mask fitted over the nose and mouth. This is followed by the ventilation component of the scan. The patient takes a deep breath of a mixture of oxygen and radioactive gas, which diffuses throughout the lungs. A scan is performed to detect ventilation abnormalities in patients who have regional differences in ventilation. It may be helpful in the diagnosis of bronchitis, asthma, inflammatory fibrosis, pneumonia, emphysema, and lung cancer. Ventilation without perfusion is seen with pulmonary emboli.

A gallium scan is a radioisotope lung scan used to detect inflammatory conditions, abscesses, adhesions, and the presence, location, and size of tumors. It is used to stage bronchogenic cancer and document tumor regression after chemotherapy or radiation. Gallium is injected intravenously, and scans are taken at intervals (eg, 6, 24, and 48 hours) to evaluate gallium uptake by the pulmonary tissues.

PET is a radioisotope study with advanced diagnostic capabilities that is used to evaluate lung nodules for malignancy. PET can detect and display metabolic changes in tissue, distinguish normal tissue from diseased tissue (such as

in cancer), differentiate viable from dead or dying tissue, show regional blood flow, and determine the distribution and fate of medications in the body. PET is more accurate in detecting malignancies than CT and has equivalent accuracy in detecting malignant nodules when compared with invasive procedures such as thoracoscopy.

Endoscopic Procedures

Endoscopic procedures include bronchoscopy, thoracoscopy, and thoracentesis.

Bronchoscopy

Bronchoscopy is the direct inspection and examination of the larynx, trachea, and bronchi through either a flexible fiberoptic bronchoscope or a rigid bronchoscope (Fig. 21-13). The fiberoptic scope is used more frequently in current practice.

Procedure

The purposes of diagnostic bronchoscopy are: (1) to examine tissues or collect secretions, (2) to determine the location and extent of the pathologic process and to obtain a tissue sample for diagnosis (by biting or cutting forceps, curettage, or brush biopsy), (3) to determine whether a tumor can be resected surgically, and (4) to diagnose bleeding sites (source of hemoptysis).

Therapeutic bronchoscopy is used to (1) remove foreign bodies from the tracheobronchial tree, (2) remove secretions obstructing the tracheobronchial tree when the patient cannot clear them, (3) treat postoperative atelectasis, and (4) destroy and excise lesions. It has also been used to insert stents to relieve airway obstruction that is caused by tumors or miscellaneous benign conditions or that occurs as a complication of lung transplantation.

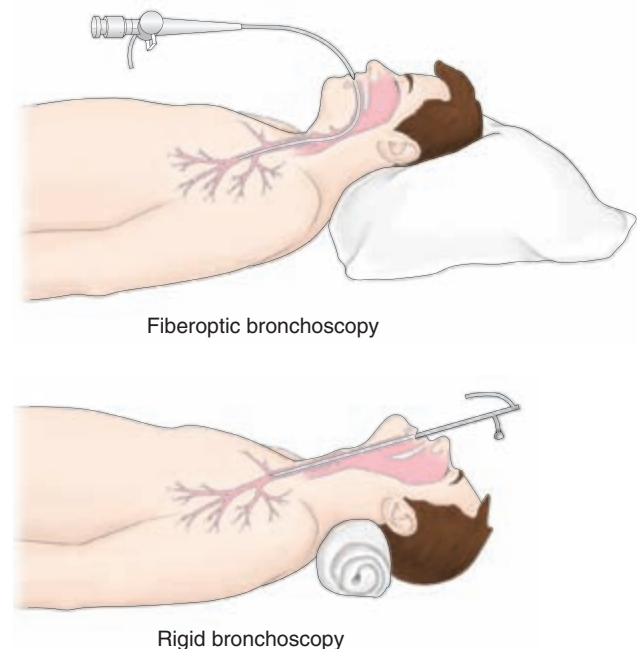


Figure 21-13 Endoscopic bronchoscopy permits visualization of bronchial structures. The bronchoscope is advanced into bronchial structures orally. Bronchoscopy permits the clinician not only to diagnose but also to treat various lung problems.

The fiberoptic bronchoscope is a thin, flexible bronchoscope that can be directed into the segmental bronchi. Because of its small size, its flexibility, and its excellent optical system, it allows increased visualization of the peripheral airways and is ideal for diagnosing pulmonary lesions. Fiberoptic bronchoscopy allows biopsy of previously inaccessible tumors and can be performed at the bedside. It also can be performed through endotracheal or tracheostomy tubes of patients on ventilators. Cytologic examinations can be performed without surgical intervention.

The rigid bronchoscope is a hollow metal tube with a light at its end. It is used mainly for removing foreign substances, investigating the source of massive hemoptysis, or performing endobronchial surgical procedures. Rigid bronchoscopy is performed in the operating room, not at the bedside.

Possible complications of bronchoscopy include a reaction to the local anesthetic, infection, aspiration, bronchospasm, **hypoxemia** (low blood oxygen level), pneumothorax, bleeding, and perforation.

Nursing Interventions

Before the procedure, a signed consent form is obtained from the patient. Food and fluids are withheld for 6 hours before the test to reduce the risk of aspiration when the cough reflex is blocked by anesthesia. The nurse explains the procedure to the patient to reduce fear and decrease anxiety and administers preoperative medications (usually atropine and a sedative or opioid) as prescribed to inhibit vagal stimulation (thereby guarding against bradycardia, dysrhythmias, and hypotension), suppress the cough reflex, sedate the patient, and relieve anxiety.

NURSING ALERT

Sedation given to patients with respiratory insufficiency may precipitate respiratory arrest.

The patient must remove dentures and other oral prostheses. The examination is usually performed under local anesthesia or moderate sedation, but general anesthesia may be used for rigid bronchoscopy. A topical anesthetic such as lidocaine (Xylocaine) may be sprayed on the pharynx or dropped on the epiglottis and vocal cords and into the trachea to suppress the cough reflex and minimize discomfort. Sedatives or opioids are administered intravenously as prescribed to provide moderate sedation.

After the procedure, it is important that the patient takes nothing by mouth until the cough reflex returns, because the preoperative sedation and local anesthesia impair the protective laryngeal reflex and swallowing for several hours. Once the patient demonstrates a cough reflex, the nurse may offer ice chips and eventually fluids. In the elderly patient, the nurse assesses for confusion and lethargy, which may be due to the large doses of lidocaine administered during the procedure. The nurse also monitors the patient's respiratory status and observes for hypoxia, hypotension, tachycardia, dysrhythmias, hemoptysis, and dyspnea. Any abnormality is reported promptly. The patient is not discharged from the recovery area until adequate cough reflex and respiratory status are present. The nurse instructs

the patient and family caregivers to report any shortness of breath or bleeding immediately.

Thoracoscopy

Thoracoscopy is a diagnostic procedure in which the pleural cavity is examined with an endoscope (Fig. 21-14).

Procedure

Small incisions are made into the pleural cavity in an intercostal space; the location of the incision depends on the clinical and diagnostic findings. After any fluid present in the pleural cavity is aspirated, the fiberoptic mediastinoscope is inserted into the pleural cavity, and its surface is inspected through the instrument. After the procedure, a chest tube may be inserted, and the pleural cavity is drained by negative-pressure water-seal drainage.

Thoracoscopy is primarily indicated in the diagnostic evaluation of pleural effusions, pleural disease, and tumor staging. Biopsies of the lesions can be performed under visualization for diagnosis.

Thoracoscopic procedures have expanded with the availability of video monitoring, which permits improved visualization of the lung. Video-assisted thoracoscopy (VATS) may be used in the diagnosis and treatment of emphysema, pleural effusion, and other respiratory disorders

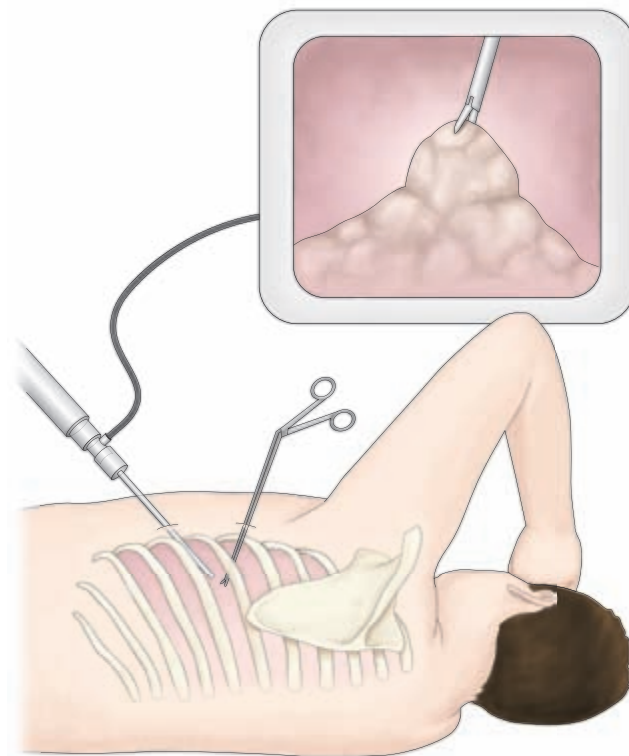


Figure 21-14 Endoscopic thoracoscopy. Like bronchoscopy, thoracoscopy uses fiberoptic instruments and video cameras for visualizing thoracic structures. Unlike bronchoscopy, thoracoscopy usually requires the surgeon to make a small incision before inserting the endoscope. A combined diagnostic-treatment procedure, thoracoscopy includes excising tissue for biopsy.

(Luh, Chou, Wang, et al., 2005). Such procedures also have been used with the carbon dioxide laser in the removal of pulmonary blebs and bullae and in the treatment of spontaneous pneumothorax. Lasers have also been used in the excision of peripheral pulmonary nodules. Although the laser does not replace the need for thoracotomy in the treatment of some lung cancers, its use continues to expand, because it is less invasive than open surgical procedures and hospitalization and recovery are shorter.

Nursing Interventions

Follow-up care in the health care facility and at home involves monitoring the patient for shortness of breath (which might indicate a pneumothorax) and minor activity restrictions, which vary depending on the intensity of the procedure. If a chest tube was inserted during the procedure, monitoring of the chest drainage system and chest tube insertion site is essential (see Chapter 25).

Thoracentesis

A thin layer of pleural fluid normally remains in the pleural space. An accumulation of pleural fluid may occur with some disorders. Thoracentesis (aspiration of fluid or air from the pleural space) is performed for diagnostic or therapeutic reasons (Chart 21-10). Purposes of the procedure include removal of fluid and air from the pleural cavity, aspiration of pleural fluid for analysis, pleural biopsy, and instillation of medication into the pleural space. When performed for biopsy, studies of pleural fluid include Gram stain culture and sensitivity, acid-fast staining and culture, differential cell count, cytology, pH, specific gravity, total protein, and lactic dehydrogenase. When thoracentesis is performed under ultrasound guidance, it has a lower rate of complications than when it is performed without ultrasound guidance.

Biopsy

Biopsy, the excision of a small amount of tissue, may be performed to permit examination of cells from the pharynx, larynx, and nasal passages. Local, topical, moderate sedation, or general anesthesia may be administered, depending on the site and the procedure.

Pleural Biopsy

Pleural biopsy is accomplished by needle biopsy of the pleura or by pleuroscopy, a visual exploration through a fiberoptic bronchoscope inserted into the pleural space. Pleural biopsy is performed when there is pleural exudate of undetermined origin or when there is a need to culture or stain the tissue to identify tuberculosis or fungi.

Lung Biopsy Procedures

If the chest x-ray findings are inconclusive or show pulmonary density (indicating an infiltrate or lesion), biopsy may be performed to obtain lung tissue for examination to identify the nature of the lesion. Several nonsurgical lung biopsy techniques are used because they yield accurate information with low morbidity: transcatheter bronchial brushing, transbronchial lung biopsy, and percutaneous (through-the-skin) needle biopsy.

Procedure

In transcatheter bronchial brushing, a fiberoptic bronchoscope is introduced into the bronchus under fluoroscopy. A small brush attached to the end of a flexible wire is inserted through the bronchoscope. Under direct visualization, the area under suspicion is brushed back and forth, causing cells to slough off and adhere to the brush. The catheter port of the bronchoscope may be used to irrigate the lung tissue with saline solution to secure material for additional studies. The brush is removed from the bronchoscope and a slide is made for examination under the microscope. The brush may be cut off and sent to the pathology laboratory for analysis.

This procedure is useful for cytologic evaluations of lung lesions and for the identification of pathogenic organisms (eg, *Nocardia*, *Aspergillus*, *Pneumocystis jiroveci*). It is especially useful in the immunologically compromised patient.

Another method of bronchial brushing involves the introduction of the catheter through the cricothyroid membrane by needle puncture. After this procedure, the patient is instructed to hold a finger or thumb over the puncture site while coughing to prevent air from leaking into the surrounding tissues.

In transbronchial lung biopsy, biting or cutting forceps are introduced by a fiberoptic bronchoscope. A biopsy is indicated when a lung lesion is suspected and the results of routine sputum samples and bronchoscopic washings are negative.

In percutaneous needle biopsy, a cutting needle or a spinal-type needle is used to obtain a tissue specimen for histologic study. Analgesia may be administered before the procedure. The skin over the biopsy site is cleansed and anesthetized, and a small incision is made. The biopsy needle is inserted through the incision into the pleura with the patient holding his or her breath in midexpiration. Using fluoroscopic monitoring, the surgeon guides the needle into the periphery of the lesion and obtains a tissue sample from the mass. Possible complications include pneumothorax, pulmonary hemorrhage, and empyema.

Nursing Interventions

After the procedure, recovery and home care are similar to those for bronchoscopy and thoracoscopy. Nursing care involves monitoring the patient for shortness of breath, bleeding, and infection. In preparation for discharge, the patient and family are instructed to report pain, shortness of breath, visible bleeding, redness of the biopsy site, or purulent drainage (pus) to the health care provider immediately. Patients who have undergone biopsy are often anxious because of the need for the biopsy and the potential findings; the nurse must consider this in providing postbiopsy care and teaching.

Lymph Node Biopsy

The scalene lymph nodes are enmeshed in the deep cervical pad of fat overlying the scalenus anterior muscle. They drain the lungs and mediastinum and may show histologic changes from intrathoracic disease. If these nodes are palpable on physical examination, a scalene node biopsy may

CHART
21-10

Guidelines for Assisting the Patient Undergoing Thoracentesis

Equipment

- Thoracentesis tray
- Sterile gloves
- Germicide solution
- Local anesthetic
- Sterile collection bottles

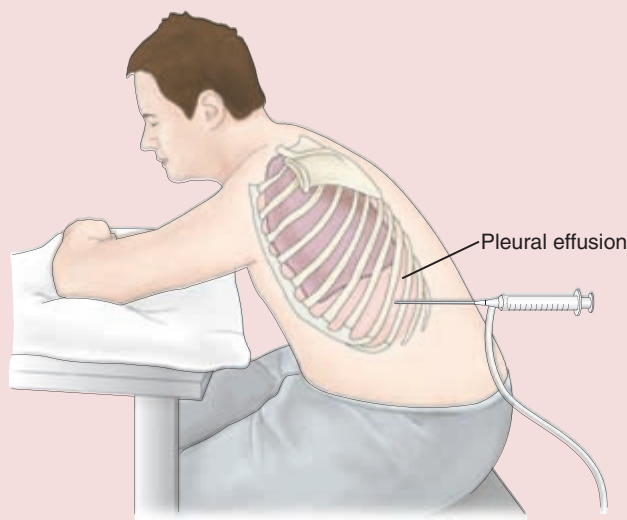
Implementation

Action

1. Ascertain in advance that a chest x-ray has been ordered and completed and the consent form for thoracentesis has been signed.
2. Assess the patient for allergy to the local anesthetic to be used.
3. Administer sedation if prescribed.
4. Inform the patient about the nature of the procedure and
 - a. The importance of remaining immobile
 - b. Pressure sensations to be experienced
 - c. That minimal discomfort is anticipated after the procedure.
5. Position the patient comfortably with adequate supports. If possible, place the patient upright or in one of the following positions:
 - a. Sitting on the edge of the bed with the feet supported and arms on a padded over-the-bed table
 - b. Straddling a chair with arms and head resting on the back of the chair
 - c. Lying on the unaffected side with the head of the bed elevated 30 to 45 degrees if unable to assume a sitting position.

Rationale

1. Posteroanterior and lateral chest x-ray films are used to localize fluid and air in the pleural cavity and to aid in determining the puncture site. When fluid is loculated (isolated in a pocket of pleural fluid), ultrasound scans are performed to help select the best site for needle aspiration.
2. If the patient is allergic to the initially prescribed anesthetic, assessment findings provide an opportunity to use a safer anesthetic.
3. Sedation enables the patient to cooperate with the procedure and promotes relaxation.
4. An explanation helps to orient the patient to the procedure, assists the patient to mobilize resources, and provides an opportunity to ask questions and verbalize anxiety.
5. The upright position facilitates the removal of fluid that usually localizes at the base of the thorax. A position of comfort helps the patient to relax.



Continued on following page


 CHART
21-10

Guidelines for Assisting the Patient Undergoing Thoracentesis (Continued)

Action

6. Support and reassure the patient during the procedure.
 - a. Prepare the patient for the cold sensation of skin germicide solution and for a pressure sensation from infiltration of local anesthetic agent.
 - b. Encourage the patient to refrain from coughing.
7. Expose the entire chest. The site for aspiration is visualized by chest x-ray and percussion. If fluid is in the pleural cavity, the thoracentesis site is determined by the chest x-ray, ultrasound scanning, and physical findings, with attention to the site of maximal dullness on percussion.
8. The procedure is performed under aseptic conditions. After the skin is cleansed, the physician uses a small-caliber needle to inject a local anesthetic slowly into the intercostal space.
9. The physician advances the thoracentesis needle with the syringe attached. When the pleural space is reached, suction may be applied with the syringe.
 - a. A 20-mL syringe with a three-way stopcock is attached to the needle (one end of the adapter is attached to the needle and the other to the tubing leading to a receptacle that receives the fluid being aspirated).
 - b. If a considerable quantity of fluid is removed, the needle is held in place on the chest wall with a small hemostat.
10. After the needle is withdrawn, pressure is applied over the puncture site and a small, airtight, sterile dressing is fixed in place.
11. Advise the patient that he or she will be on bed rest and a chest x-ray will be obtained after thoracentesis.
12. Record the total amount of fluid withdrawn from the procedure and document the nature of the fluid, its color, and its viscosity. If indicated, prepare samples of fluid for laboratory evaluation. A specimen container with formalin may be needed for a pleural biopsy.
13. Monitor the patient at intervals for increasing respiratory rate; asymmetry in respiratory movement; faintness; vertigo; tightness in chest; uncontrollable cough; blood-tinged, frothy mucus; a rapid pulse; and signs of hypoxemia.

Rationale

6. Sudden and unexpected movement, such as coughing, by the patient can traumatize the visceral pleura and lung.
7. If air is in the pleural cavity, the thoracentesis site is usually in the second or third intercostal space in the midclavicular line because air rises in the thorax.
8. An intradermal wheal is raised slowly; rapid injection causes pain. The parietal pleura is very sensitive and should be well infiltrated with anesthetic before the physician passes the thoracentesis needle through it.
9. Use of thoracentesis needle allows proper insertion.
 - a. When a large quantity of fluid is withdrawn, a three-way stopcock serves to keep air from entering the pleural cavity.
 - b. The hemostat steadies the needle on the chest wall. Sudden pleuritic chest pain or shoulder pain may indicate that the needle point is irritating the visceral or the diaphragmatic pleura.
10. Pressure helps to stop bleeding, and the airtight dressing protects the site and prevents air from entering the pleural cavity.
11. A chest x-ray verifies that there is no pneumothorax.
12. The fluid may be clear, serous, bloody, purulent, etc.
13. Pneumothorax, tension pneumothorax, subcutaneous emphysema, and pyogenic infection are complications of a thoracentesis. Pulmonary edema or cardiac distress can occur after a sudden shift in mediastinal contents when large amounts of fluid are aspirated.

be performed. A biopsy of these nodes may be performed to detect spread of pulmonary disease to the lymph nodes and to establish a diagnosis or prognosis in such diseases as Hodgkin lymphoma, sarcoidosis, fungal disease, tuberculosis, and carcinoma.

Procedure

Mediastinoscopy is the endoscopic examination of the mediastinum for exploration and biopsy of mediastinal lymph nodes that drain the lungs; this examination does not require a thoracotomy. Biopsy is usually performed through a suprasternal incision. Mediastinoscopy is carried out to detect mediastinal involvement of pulmonary malignancy and to obtain tissue for diagnostic studies of other conditions (eg, sarcoidosis).

An anterior mediastinotomy is thought to provide better exposure and diagnostic possibilities than a mediastinoscopy.

An incision is made in the area of the second or third costal cartilage. The mediastinum is explored, and biopsies are performed on any lymph nodes found. Chest tube drainage is required after the procedure. Mediastinotomy is particularly valuable to determine whether a pulmonary lesion is resectable.

Nursing Interventions

Postprocedure care focuses on providing adequate oxygenation, monitoring for bleeding, and providing pain relief. The patient may be discharged a few hours after the chest drainage system is removed. The nurse should instruct the patient and family about monitoring for changes in respiratory status, taking into consideration the impact of anxiety about the potential findings of the biopsy on their ability to remember those instructions.

CRITICAL THINKING EXERCISES

1 A 48-year-old woman with a long history of smoking (40 pack-years) is scheduled for surgery under general anesthesia to remove a lump from her breast. In preparation for surgery, she is scheduled for PFTs, which she refuses to have because she says her breathing is fine and has nothing to do with her breasts. How would you respond to her statement? What impact does her 40 pack-year history of cigarette smoking have on your preoperative, intraoperative, and postoperative assessment?

2 You are obtaining a health history from a 62-year-old patient who is seeking health care because of a persistent cough and extreme fatigue. She mentions that she cannot keep up with her grandchildren and even gets out of breath when reading to them or talking to them on the phone. What specific information about signs and symptoms would you obtain during the health history? How would you modify your physical examination based on your observations? What initial laboratory tests would you anticipate will be ordered for this patient?

3 An 88-year-old man has been recently relocated because his family does not want him to live by himself. He has never been seen at this pulmonary clinic and is here to get acquainted with his new health care providers. He says his lungs are “no good” because he has smoked since he was 18 years old and was exposed to asbestos during the 15 years he worked in shipyards. He brought a folder from his previous health care provider with results of tests that were done during a hospitalization for pneumonia 2 years earlier: PFTs, ABCs, sputum cultures, chest x-ray, and CT scan of the chest. What questions will you ask him about his health history? What tests do you anticipate being repeated at this time and why?

EBP **4** A 70-year-old patient who has cancer of the lung has undergone a thoracentesis with removal of 750 mL of pleural fluid to relieve his shortness of breath. Soon after the procedure is completed, the patient reports that his shortness of breath has increased rather than decreased. Based on your knowledge of risks associated with thoracentesis, what assessment data would you obtain from this patient and report to the physician? What additional nursing measures are warranted for the patient at this time? What is the evidence on which your nursing interventions are based? How would you determine the strength of that evidence? How would you respond if the patient had been discharged an hour after the thoracentesis and provided this information to you by telephone from home?



The Smeltzer suite offers these additional resources to enhance learning and facilitate understanding of this chapter:

- thePoint on line resource, thepoint.lww.com/Smeltzer12E
- Student CD-ROM included with the book
- *Study Guide to Accompany Brunner & Suddarth's Textbook of Medical-Surgical Nursing*

REFERENCES AND SELECTED READINGS

*Asterisks indicates nursing research.

Books

- Aehlert, B. (2007). *ACLS study guide* (3rd ed.). St. Louis: Mosby.
- Bickley, L. S. (2007). *Bates' guide to physical examination and history taking* (9th ed.). Philadelphia: Lippincott Williams & Wilkins.
- Pierce, L. N. B. (2007). *Management of the mechanically ventilated patient* (2nd ed.). St. Louis: Saunders.
- Porth, C. M. & Matfin, G. (2009). *Pathophysiology: Concepts of altered health states* (8th ed.). Philadelphia: Lippincott Williams & Wilkins.
- Springhouse. (2007). *RN expert guides: Respiratory care*. Philadelphia: Lippincott Williams & Wilkins.
- Urden, L. D., Stacy, K. M. & Lough, M. E. (2005). *Thelan's critical care nursing: Diagnosis and management* (5th ed.). St. Louis: Mosby.
- Weber, J. R. & Kelley, J. (2010). *Health assessment in nursing* (4th ed.). Philadelphia: Lippincott Williams & Wilkins.
- West, J. B. (2008). *Respiratory physiology: The essentials* (8th ed.). Philadelphia: Lippincott Williams & Wilkins.
- Wold, G. H. (2008). *Basic geriatric nursing* (4th ed.). St. Louis: Mosby.

Journals and Electronic Documents

- Allen, J. & Hart, M. (2006). Assessing exertional dyspnea in the COPD population. *AARC Times*, 12, 24–25.
- Bledsoe, B. E., Porter, R. S. & Cherry, R. A. (2005). 25 Physical examination pearls: Important tips to help you polish your hands-on patient assessment skills. *JEMS: Journal of Emergency Medical Services*, 30(3), 62–74, 77.
- Calleo-Cross, A., Sharma, N. & Aronne, L. J. (2005). Medical assessment of obese older patients. *Clinics in Geriatric Medicine*, 21(4), 689–699.
- Clark, A. P., Giuliano, K. & Chen, H. (2006). Pulse oximetry revisited: “But his O₂ sat was normal!” *Clinical Nurse Specialist*, 20(6), 268–272.
- Crawford, A. (2004). Respiratory nursing. An audit of the patient's experience of arterial blood gas testing. *British Journal of Nursing*, 13(9), 529–532.
- Davis, M. & Holliday, J. Jr. (2005). Differentiating causes of respiratory distress. *Emergency Medical Services*, 34(1), 72–73.
- Dorman, S., Byrne, A. & Edwards, A. (2007). Which measurement scales should we use to measure breathlessness in palliative care? A systematic review. *Palliative Medicine*, 21(3), 177–191.
- Fabbro, E. D., Dalal, S. & Bruera, E. (2006). Symptom control in palliative care—Part III: Dyspnea and delirium. *Journal of Palliative Medicine*, 9(2), 422–436.
- Farquhar, S. L. & Fantasia, L. (2005). Pulmonary anatomy and physiology and the effects of COPD. *Home Healthcare Nurse*, 23(3), 167–176.
- Grindel, M. E. & Grindel, C. G. (2006). Nursing care of the person having bariatric surgery. *MedSurg Nursing*, 15(3), 129–146.
- Hahler, B. (2002). Morbid obesity: A nursing care challenge. *MedSurg Nursing*, 15(6), 357–363.
- Heo, S., Moser, D. K., Lennie, T. A., et al. (2007). A comparison of health-related quality of life between older adults with heart failure and healthy older adults. *Heart & Lung*, 36(1), 16–24.
- *Hoekstra, J., Vernooij-Dassen, M. J. F., de Vos, R., et al. (2007). The added value of assessing the “most troublesome” symptom among patients with cancer in the palliative phase. *Patient Education and Counseling*, 65(2), 223–229.
- Indelicato, R. A. (2006). The advanced practice nurse's role in palliative care and the management of dyspnea. *Topics in Advanced Practice Nursing eJournal*, 6(4), 13.
- Irwin, R. S., Baumann, M. H., Bolser, D. C., et al. (2006). Diagnosis and management of cough: Executive summary. ACCP evidence-based clinical practice guidelines. *Chest*, 129(1 Suppl), 1S–23S.
- Karmani, N. G., Reisfield, G. M. & Wilson, G. R. (2005). Evaluation of chronic dyspnea. *American Family Physician*, 71(8), 1529–1538, 1473–1475, 1612.
- *Li, D. T. & Puntillo, K. (2006). A pilot study on coexisting symptoms in intensive care patients. *Applied Nursing Research*, 19(4), 216–219.
- Lim, K. G. & Morgenthaler, T. I. (2005). Defining obstruction or restriction remains the goal: Pulmonary function tests. Part 1: Applying the basics. *Journal of Respiratory Diseases*, 26(1), 26–30, 32.
- Luh, S. P., Chou, M. C., Wang, L. S., et al. (2005). Video-assisted thoracoscopic surgery in the treatment of complicated parapneumonic effusions or empyemas: Outcome of 234 patients. *Chest*, 127(4), 1427–1432.
- Malcarne, V. L., Hansdottir, I., McKinney, A., et al. (2007). Medical signs and symptoms associated with disability, pain, and psychosocial adjustment in systemic sclerosis. *Journal of Rheumatology*, 34(2), 359–367.
- Marley, R. A., Hoyle, B. & Ries, C. (2005). Perianesthesia respiratory care of the bariatric patient. *Journal of PeriAnesthesia Nursing*, 5, 404–434.

- *McMillan, S. C. & Small, B. J. (2007). Using the COPE intervention for family caregivers to improve symptoms of hospice homecare patients: A clinical trial. *Oncology Nursing Forum*, 34(2), 313–321.
- Munzer, P. (2006). Coming of age. Assessing breathlessness in older people: Focusing on patient's subjective experience. *AARC Times*, 30(12), 22, 24–25.
- Neal-Boylan, L. (2007). Health assessment of the very old person at home. *Home Healthcare Nurse*, 25(6), 388–400.
- Niven, A. S. & Weisman, I. M. (2006). Evaluating dyspnea: A practical approach. *Journal of Respiratory Diseases*, 27(1), 10–24.
- Norweg, A. M., Whiteson, J., Demetis, S., et al. (2006). A new functional status outcome measure of dyspnea and anxiety for adults with lung disease: The dyspnea management questionnaire. *Journal of Cardiopulmonary Rehabilitation*, 26(6), 395–404.
- O'Leary, N., Tiernan, E. & McDonald, K. (2006). Symptom prevalence in advanced heart failure patients attending a specialist heart failure unit. *Journal of Palliative Care*, 22(3), 232.
- Saracino, A. (2007). Review of dyspnoea quantification in the emergency department: Is a rating scale for breathlessness suitable for use as an admission prediction tool? *Emergency Medicine Australasia*, 19(5), 394–404.
- Scano, G. & Stendardi, L. (2006). Dyspnea and asthma. *Current Opinion in Pulmonary Medicine*, 12(1), 18–22.
- Thomas, P. (2005). "I can't breathe": Assessment and emergency management of acute dyspnoea. *Australian Family Physician*, 34(7), 523–529.
- Torres, M. & Moayedi, S. (2007). Evaluation of the acutely dyspneic elderly patient. *Clinics in Geriatric Medicine*, 23(2), 307–325.
- Zavorsky, G. S., Lands, L. C., Schneider, W., et al. (2005). Comparison of fingertip to arterial blood samples at rest and during exercise. *Clinical Journal of Sport Medicine*, 15(4), 261–268.

RESOURCES

- American Association for Respiratory Care, www.aarc.org
- American Lung Association, www.lungusa.org
- National Heart, Lung, and Blood Institute/National Institutes of Health, www.nhlbi.nih.gov/index.htm
- National Lung Health Education Program, www.nlhep.org (has easy-to-read teaching resources for patients)